



Fine-Needle Aspiration Versus Non Aspiration Technique of Cytodiagnosis in Thyroid Lesions

Prachi Mahajan, P R. Sharma

Abstract

The two sampling techniques were studied in 50 patients presenting with enlargement of thyroid gland. They were sampled by fine needle aspiration (FNA) and by non-aspiration (NA - a needle without application of aspiration pressure). Cell samples were cytologically assessed and were scored (0, 1 & 2) using five objective parameters which includes background blood or clot, amount of cellular material, degree of cellular degeneration, degree of cellular trauma and retention of appropriate architecture. Non-aspiration performed better than FNAC for criteria background blood or clot and retention of appropriate architecture with statistically significant difference. Non-aspiration also scored better than FNAC for the other parameters as well as cumulatively. Smears were then cytologically assessed as diagnostically inadequate, adequate and superior. Greater number of diagnostically adequate specimens were obtained by FNAC than by NA but the number of diagnostically superior specimen were obtained significantly more frequently by the non-aspiration technique. Thus, the non-aspiration technique combined with FNAC can result in obtaining good quality cellular material in thyroid lesions.

Key Words

FNAC, Non Aspiration Technique, Cytodiagnosis, Thyroid

Introduction

Fine Needle aspiration cytology (FNAC) is currently practiced worldwide. Fine aspiration cytology has proven to be an effective first line diagnostic tool in evaluating palpable thyroid lesions. It allows better selection of the patients who need to undergo a surgical procedure (1). However, in most of thyroid lesions, an unsatisfactory specimen, especially mixed with blood, poses an obstacle in proper interpretation. In an attempt to overcome the problem of vascularity of thyroid gland, an alternative sampling method was developed in France (2). It avoids aspiration, utilized only the needle and relies on the pressure to suck the cells inside the needle bore. For thyroid lesions this technique was first evaluated and compared with the conventional technique of FNAC by Santos & Leiman (1988) in 50 nodular lesions (3). With the advent of new interventional radiological techniques, most areas are accessible of FNAC(4,5). In present study fine needle aspiration and non aspiration technique were compared in palpable thyroid lesions to evaluate their diagnostic accuracy and reliability.

Materials and Methods

The present study was conducted on 50 patients presenting with a enlarged thyroid gland. All these patients

were subjected to aspiration and non-aspiration techniques. Hopper *et al.* (6) compared the two techniques using all lengths and diameters of biopsy needles. Fine needle aspiration was performed using the syringe and holder while non-aspiration techniques was done without syringe or holder. In this technique the needle, held between the thumb and forefinger of one hand, was inserted gently into the nodule and moved in different directions. Material entering the hub of the needle by capillary action was then expressed onto clean glass lights after attaching the syringe filled with air to it and smears were prepared in the usual manner (7). The wet smears were immediately fixed in isopropyl alcohol and latter stained by Papnicolaou and Hematoxylin & Eosin. Air dried smears were stained by May-Grunwald Giemsa. An individual slide was objectively analysed using points scoring system (8,9) to enable comparison between FNAC & NA techniques as shown in *table 1*.

On the basis of five criteria tabulated, a cumulative score between 0-10 points was allocated to each fine needle specimen which was then categorized to one of three categories: (i) Unsuitable for cytodiagnosis (Score 0-2); (ii) Suitable for cytodiagnosis (Score 3-

From the Department of Pathology ASCOMS & Hospital Sidhra, Jammu (J&K) - India

Correspondence to : Dr P R Sharma, Prof of Pathology , ASCOMS & Hospital Sidhra, Jammu



6);(iii)Diagnostically superior (Score 7-10).All the results were interpreted statistically using student's paired 't' test.

Results

Out of 50 cases studied (Table 2), Non neoplastic lesions comprised 80% of the total cases. They comprised mainly of Colloid goiter (19 cases), Benign thyroid hyperplasia (6 cases), Lymphocytic thyroiditis (13 cases), Granulomatous (2 cases). Out of the 10 neoplasms (20% of the total) 6 were follicular neoplasms, 2 cases of medullary and 2 of papillary carcinoma.

On categorizing all the smears obtained by FNAC and NA technique on the basis of score obtained, it was apparent (Table 3) that by FNAC we obtained greater number of diagnostically adequate (12), and lesser number of unsatisfactory smears (8) where as greater number of diagnostically superior samples were obtained by NA techniques (36) but simultaneously the number of smears showing inadequate material for diagnosis was also more in nonaspiration (10). On statistically evaluation of each category of both the techniques separately as shown in table 4. Non aspiration performed better than FNAC for criterion background blood or clot and retention of appropriate architecture with statistically significant difference (p<0.05). Non-aspiration scored better than FNAC for the other parameter as well as cumulatively but with no statistical significance.

Table 1. Point Scoring System for Specimen Quality Analysis

Criterion	Quantitative Description	Point Score
Background blood or clot	➤ Large amount: great compromise in diagnosis	0
	➤ Moderate amount: diagnosis possible	1
	➤ Minimal: diagnosis easy, specimen of text book quality.	2
Amount of Cellular material	➤ Minimal to absent: diagnosis not possible	0
	➤ Sufficient for cyto diagnosis	1
	➤ Abundant: diagnosis simple	2
Degree of Cellular degeneration	➤ Marked: diagnosis impossible	0
	➤ Moderate: diagnosis possible	1
Degree of Cellular trauma	➤ Minimal: good preservation; diagnosis easy	2
	➤ Marked: diagnosis not possible	0
Retention of appropriate Architecture	➤ Moderate: diagnosis possible	1
	➤ Minimal: diagnosis obvious	2
	➤ Minimal to absent: non-diagnostic	0
	➤ Moderate: some preservation of e.g. Follicle, papillae, acini, flat sheets, syncytia or single cell patterns.	1
	➤ Excellent architectural display closely reflecting histology: diagnosis obvious	2

Table 2. Showing cause of Thyroid Enlargement in 50 Cases

S.No.	Cause	No.	%age
01.	Colloid goiter	19	38%
02.	Benign thyroid hyperplasia	6	12%
03.	Lymphocytic thyroiditis	13	26%
04.	Granulomatous thyroiditis	2	4%
05.	Follicular neoplasm	6	12%
06.	Medullary carcinoma	2	4%
07.	Papillary carcinoma	2	4%

Table 3. Showing Performance of FNAC And FNCS in 50 Cases of Thyroid Lesions

	FNAC		FNCS	
	No.	%age	No.	%age
Diagnostically inadequate	8	16	10	20
Diagnostically adequate	12	24	4	8
Diagnostically superior	30	60	36	72

Table 4. Showing Average Score Per Case For Each Category In 50 Thyroid Lesions

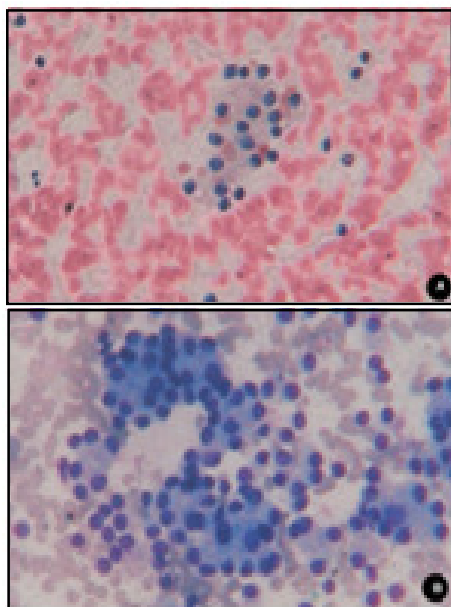
Criteria's		Total points	Mean	Standard deviation	p-value
Background blood or clot	FNAC	26.00	1.0400	0.7348	0.183
	FNCS	33.00	1.3200	0.8021	
Amount of cellular material	FNAC	32.00	1.2800	0.7371	0.627
	FNCS	34.00	1.3600	0.8103	
Degree of cellular degeneration	FNAC	37.00	1.4800	0.7141	0.852
	FNCS	38.00	1.5200	0.7703	
Degree of cellular trauma	FNAC	37.00	1.4800	0.7141	0.852
	FNCS	38.00	1.5200	0.7703	
Retention of appropriate	FNAC	22.00	0.8800	0.7257	0.110
	FNCS	28.00	1.1200	0.7257	
Total	FNAC	154.00	6.1600	2.8531	0.429
	FNCS	171.00	6.8400	3.3749	

Discussion

Fine Aspiration Cytology is an important tool for the cytological assessment of patients with superficial as well as deep seated lesions. But this technique is frequently complicated by aspiration of significant quantities of blood particularly in vascular organs or haemorrhagic tumours which compromise cellular preservation and interpretation. In an attempt to overcome this problem a non-aspiration technique was pioneered in France. This technique employs insertion of fine needle into lesions without attachment of a syringe. It relies on the property of capillary tension in narrow channel.

This physical principle states a fluid or semifluid substances will ascent spontaneously in a narrow tube in inverse proportion to the diameter of the tube or capillary (4). This modified technique of fine needle biopsy, first introduced by Zajdela *et al.* was called cytopuncture or Non-Aspiration (10). In the present study the overall diagnostic accuracy was 84% by FNAC and 80% by NA technique. Akhtar *et al.* (1989) concluded that there is no significant difference in the amount of cellular material obtained by two techniques(11).

The cumulative score as well as mean score of individual criteria studied was more for NA I.e. amount of material was more with less contamination with blood and better preservation of cellular morphology and architecture(12,13, 14). This was mainly because of the fact that dilution of cellular material with blood is a main

**A Case Diagnosed as Follicular Neoplasm of Thyroid****A. On FNAC Showing Scanty Material (H & E X 400)****B. On NA Show Cellular Smear with Typical Microfollicles and Acinar like Structures (MGG X 400)**

cause of more number of inadequate smears by FNAC. This is minimal with NA because of spontaneous ascent of material by capillary action and significant reduction in trauma to the lesion and surrounding tissues(15).

It was observed that both the techniques have their own advantages and disadvantages. FNAC smears give adequate result in most of the cases. In addition simple benign lesion or abscesses which can be drained by aspiration for therapeutic purpose. Non-aspiration technique is less traumatic, produces less bloody samples, allows a more sensitive fingertip feeling of lesion and improves the precision in the sampling of small lesions(16-19). It provides textbook quality specimen of superior diagnostic value. Moreover, this technique is cheaper, simple and well tolerated by children (5). This technique is not suitable in cystic, bony & fibrous lesions(20).

Conclusion

Thus, non-aspiration techniques combined with FNAC can result in obtaining good quality cellular material in thyroid lesions.

References

- Lowhagen T, Willems JS, Lundell G, Sundblad R, Granberg P. Aspiration biopsy cytology in diagnosis of thyroid cancer. *World J Surg* 1981; 61-73.
- Briffod M, Gentile A, Hebert H. Cytopuncture in the follow up of breast carcinoma. *Acta Cytol* 1982; 26(2): 195-200.
- Santos JEC, Leiman G. Non aspiration fine needle cytology: Application of a new technique to nodular thyroid disease. *Acta Cytol* 1988; 32 (3): 353-56.
- Redman R, Zalaznick H, Mazzaferri EL, Massoli NA. The impact of assessing specimen adequacy and number of needle passes for fine-needle aspiration biopsy of thyroid nodules. *Thyroid* 2006; 16: 55-60.
- Tublin ME, Martin JA, Rollin LJ, Lasky MK, Ohori NP. Ultrasound guided fine-needle aspiration versus fine-needle capillary sampling biopsy of thyroid nodules. *J Ultrasound Med* 2007; 26: 1697-701.
- Hopper KD, Grenko RT, Fisher AL, Tenhave TR. Capillary versus aspiration biopsy: effect of needle size and length on the cytopathological specimen quality. *Cardiovasc Intervent Radiol* 1996; 19: 341-44.
- Orell SR, Sterrett GF, Whitaker D. Manual and Atlas of fine needle aspiration cytology 4th editions; Churchill Livingstone 2005. pp. 2-13.
- Haddadi-Nehzad S, Larijan B, Tavangar SM, Nouraei SM. Comparison of fine-needle-non-aspiration with fine-needle-aspiration technique in the cytologic studies of thyroid nodules. *Endocr Pathol* 2003; 14: 369-73.
- Mair S, Dunbar F, Becker PJ, Du Plessis WD. Fine needle cytology; Is aspiration suction necessary? *Acta Cytol* 1989; 33 (6): 809-13.
- Zajdela A, Zillhardt P, Voillemot N. Cytological diagnosis by fine needle sampling without aspiration. *Cancer* 1987; 59: 1201- 05.
- Akhtar M, Ali MA, Huq M, Faulkner C. Fine needle biopsy: comparison of cellular yield with and without aspiration. *Diagn Cytopathol* 1989; 5 (2): 162-65.
- Ghosh A, Misra RK, Sharma SP, Singh HN, Chaturvedi AK. Aspiration versus non- aspiration technique of cytodiagnosis - A critical evaluation in 160 cases. *Indian J Pathol Microbiol* 2000; 43 (2): 107-12.
- Kamal MM, Arjune DG, Kulkarni HR. Comparative study of fine needle aspiration and fine needle capillary sampling of thyroid lesions. *Acta Cytol* 2002; 46 (1): 30-34.
- Kumarasinghe MP, Sherifdeen AH. Fine needle sampling without aspiration. *Pathology* 1995; 27(4): 330-32.
- Ali Rizvi SA, Husain M, Khan S, Mohsin M. A comparative study of fine needle aspiration cytology versus non-aspiration technique in thyroid lesions. *Surgeon* 2005; 3(4): 273-76.
- Al Khattab YE, Hussein AG. Fine needle capillary technique: Is aspiration suction necessary? A Study of 30 cases at various pathological lesions. *Iraqi J Med Sci* 2004; 3(2): 128-31.
- Braun H, Walch C, Beham A, Monifar I. Fine needle capillary versus fine needle aspiration cytology - a comparison of quality between puncture technique in the ENT area. *Laryngorhinootologie* 1977; 76(6): 358-63.
- Briffod M. Cytological diagnosis by fine needle sampling without aspiration. *Cancer* 1988;72:1282.
- Ciatto S, Lossa A, Cichi P, Paulin I, Bonardil L, Cerrini C. Non aspiration Fine Needle Cytology of thyroid tumors. *Acta Cytolo* 1989; 33 (6):939
- Dey P, Ray R. Comparison of fine needle sampling by capillary action and fine needle aspiration. *Cytopathology* 1993; 4 (5): 299-303.