



CASE REPORT

Placental Site Trophoblastic Tumor of the Uterus: A Mistaken Diagnosis

Nupur Gupta, J B Sharma, Suneeta Mittal, Divya Talwar, Lalit Kumar*, Manu Kukreja**

Abstract

Placental site trophoblastic tumor (PSTT) is the rarest form of Gestational Trophoblastic Neoplasia (GTN). We present this case of uterine PSTT to illustrate the difficulties in the diagnosis of this tumor and how this led to delay in its appropriate management..

Key Words

Placental site trophoblastic tumor (PSTT), Gestational Trophoblastic Neoplasia, Uterine

Introduction

Placental site trophoblastic tumor (PSTT) is the rarest form of Gestational Trophoblastic Neoplasia (GTN) (1). It has a wide clinical spectrum of presentation and behavior, ranging from a benign condition to an aggressive disease with a fatal outcome; 100 cases (uterine and extrauterine) reported in literature (1,2). Our aim of presenting this case of uterine PSTT is to illustrate the difficulties in the diagnosis of this tumor and how this led to delay in its appropriate management.

Case Report

A 22 year-old-primipara presented to us with continuous bleeding per vaginum 2 months after an uncomplicated vaginal delivery of a male infant at a district hospital. She had two bouts of excessive bleeding; first on postpartum day 20 and second on day 30. Dilatation and curettage was done on both occasions but no tissue was sent for sampling. She continued to bleed and a repeat ultrasound pelvis with Color Doppler showed a large heterogeneous echoic shadow of 6x6x3-cm size with increased vascularity in the uterus. On examination, there was marked pallor and she received three units of blood transfusion. Local examination showed healthy external genitalia, healthy cervix, a bulky uterus on per vaginal examination with free fornices. HCG done at this time was 26,000 mIU/ml. Changes in beta HCG levels that followed later during the course of chemotherapy have been depicted in Fig 1. In view of high beta HCG levels, provisional diagnosis of choriocarcinoma was made and chemotherapy was given for 6 cycles (methotrexate and folinic acid) but intermittently, heavy bleeding continued. Diagnostic difficulty was due to a poor response to chemotherapy and variable rise and fall of HCG levels.

She then received EMACO (etoposide, methotrexate, actinomycin D, cyclophosphamide and vincristine) for 3 cycles followed by emergency total abdominal hysterectomy due to profuse bleeding. On histopathological examination of the specimen, a diagnosis of malignant PSTT (placental site trophoblastic tumor) was made. Microscopic examination showed monophasic cellular pattern, large trophoblastic cells with abundant eosinophilic cytoplasm and nuclear pleomorphism. The tumor 2 x 2 cm was limited to inner half of myometrium with frequent areas of mitosis (more than 4 per 10 HPF) and necrosis (Fig 2, 3). Cells were also positive focally for beta HCG and cytokeratin. pMBP and hPL were not done as they were not available in our setup. Postoperatively, 3 weeks later, she developed lung metastasis diagnosed clinically and confirmed by CAT scan and was restarted on EMA/CO regime. Presently, she is on regular follow up with HCG levels and has completed her 6th course of EMA/CO chemotherapy, with the last three HCG values negative till date.

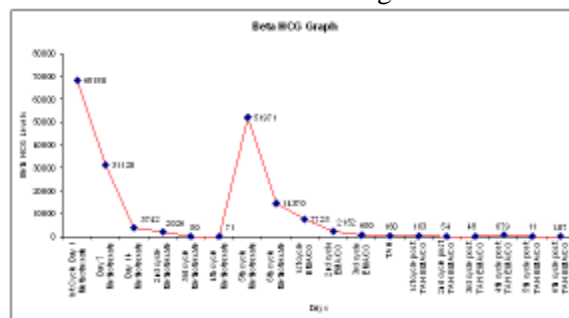


Fig 1. Changes in HCG levels (mIU/ml) During the Course of Chemotherapy TAH (Total Abdominal Hysterectomy)

From the Department of Obstetrics & Gynaecology, *Medical Oncology & **Pathology, AIIMS, New Delhi, India

Correspondence to : Dr Nupur Gupta, D-34, Pamposh Enclave, Greater Kailash-1 New Delhi - 110048 India

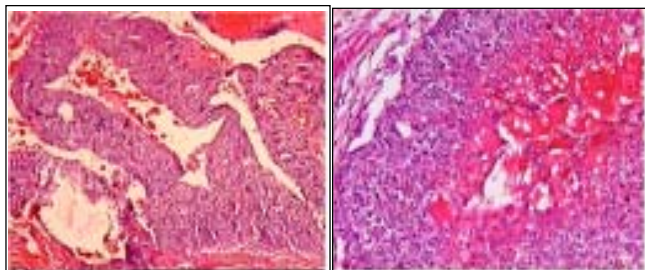


Fig 2 & 3 (4X) Localised Collection of Numerous Intermediate Trophoblasts in the Wall & Lumen(10X) Tumor Composed of Intetermediate Trophoblastic Cells, Eosinophilic Cytoplasm & Areas of Necrosis

Discussion

PSTT is an extravillous infiltrating tumor, which causes invasion of myometrium and mainly consists of intermediate trophoblasts. It was first described by Kurman et al, and named it as "trophoblastic pseudotumor" in 1976 to convey the benign nature of this tumor (3). Scully and Young coined the term placental site trophoblastic tumor to describe its malignant potential in 1981, when the first fatal case was reported (4). PSTT may complicate or follow any type of normal or abnormal pregnancy (hydatiform mole) and its interval may vary from weeks to years after the preceding pregnancy. Histologically, PSTT consists of a monomorphic population of nonvillous trophoblast derived from the intermediate trophoblasts of placental bed. Necrosis is common but hemorrhage is relatively not found as is typical of choriocarcinoma. In our case, a diagnosis of PSTT was made 6 months after a normal vaginal delivery. A delay in diagnosis was caused by a misinterpretation of her signs and symptoms; it was considered to be retained placental products initially and choriocarcinoma later. Diagnosis of PSTT is usually made after hysterectomy on histopathological findings. Difficult diagnosis was due to high beta HCG levels which can occur in a few cases of PSTT with malignant behaviour. Clinical presentation is a major prognostic variable, and is associated with a poor prognosis if last pregnancy was > 2 years prior to its presentation (5). Most of the cells of PSTT contain hPL and a minority contains ?HCG. Therefore, beta HCG cannot be used reliably to monitor its course. But in approximately 15% of PSTTs, there may be equal distribution of beta HCG and hPL (6). PSTTs that secrete more HCG are more aggressive as they resemble choriocarcinomas. Metastasis may be seen in 10-15% cases mainly to the lungs (as in our patient), lymph node, brain, liver, kidney, vagina, stomach and spleen. Extrauterine spread of disease and FIGO staging are the most important prognostic factors for progression of PSTT. How *et al* reported that in patients with >5

mitotic counts /10 HPF, the likelihood of fatal outcome was 14 times higher (7). The cornerstone of therapy is surgery with hysterectomy (with or without ovarian conservation) being the optimal management once the diagnosis of PSTT is established (8). Conservative surgery (curettage or conservative resection) can be offered to women with low mitotic ratio who wish to conceive, in whom there is no uterine enlargement and are kept on close monitoring. As compared to other forms of GTN, it is less chemosensitive. Chemotherapy {EMA/CO or EMA/EP (etoposide, methotrexate, actinomycin-D, cyclophosphamide, oncovin and cisplatin)} should be considered for metastatic lesions and radiation for localized and isolated recurrences. Our patient was initially managed as a case of choriocarcinoma on clinical grounds but subsequent histopathological evaluation of the hysterectomy specimen re-classified the tumor as PSTT.

Conclusion

PSTT is potentially curable despite being a rare tumor with unpredictable biological behavior. Hysteroscopically guided uterine biopsy and thorough histopathological evaluation is essential for reliable diagnosis in a patient not responding to chemotherapy. For patients with disease localized to the uterus, surgery remains the mainstay of therapy in the first instance, in contrast to other GTDs, because of its low chemosensitivity. EMA/CO chemotherapy should be considered for metastatic lesions, although experience is quite limited but documentation of more clinically treated cases will provide a definitive response rate.

References

1. Whitney KA. Placental site trophoblastic tumor. *Am J Nurs* 2009; 109(12):32-7
2. He YM, Yao XY, Yang KX. Placental site trophoblastic tumor occurring in uterine cervix: report of a case *Zhonghua Bing Li Xue Za Zhi*. 2009; 38(9): 631-2
3. Kurman RJ, Scully RE, Norris, HJ. Trophoblastic pseudotumor of the uterus. An exaggerated form of "Syncytial endometritis, simulating a malignant tumor. *Cancer* 1976; 7:1214-26
4. Scully RE, Young RG. Trophoblastic pseudotumor: A reappraisal. *Am J Surg Pathol*. 1981; 7: 75-76.
5. Newlands ES, Bower M, Fisher RA, Paradinas FJ. Management of placental site trophoblastic tumors. *J Reprod Med* 1998; 43: 53-59.
6. Kurman RJ, Young RH, Norris HJ, *et al*. Immunocytochemical localization of placental lactogen and chorionic gonadotropin in the normal placenta and trophoblastic tumors, with emphasis on intermediate trophoblast and the placental site trophoblastic tumor. *Int J Gynecol Pathol* 1984; 3: 101-21.
7. How J, Curry J, Grant P, *et al*. Placental site trophoblastic tumor. Report of three cases and review of the literature. *Int J Gynecol Cancer* 1995; 5: 241-49.
8. Young RE, Scully RE. Placental site trophoblastic tumor: Current status. *Clin Obstet Gynecol* 1984; 27: 1.