



Intrathoracic Prick

A Lal, S Vyas, N Khandelwal

A 37-year female presented fever one week. Chest radiograph showed dense nodular opacity in the left upper zone. Chest CT showed prick like approximately 4cm long osteochondroma, arising from antero-lateral aspect of fourth rib, pointing postero-medially towards the lung with thickened pleura overlying it. No focal parenchymal lesion, pleural or pericardial effusion seen.

Osteochondroma or exostosis is benign developmental abnormality which present as stalked bony protuberance with a cartilaginous cap. It is due to separation of a portion of the epiphyseal growth plate cartilage from the main epiphysis. Osteochondroma of rib are extremely rare, constitute about 1% of all osteochondroma, and nearly 50% of all benign rib tumour (1,2). Costal osteochondroma show male predominance and usually diagnosed in the second decade of life. Costal exostosis can be diagnosed by chest radiograph; however chest CT is useful to establish the diagnosis and to look for any Intrathoracic abnormalities or complication associated with it. They are usually asymptomatic but can rarely present with chronic complications like pneumonitis, empyema, and life threatening complications such as hemothorax due to injury to pleura, diaphragm, heart or lung (2). Complications with costal osteochondroma are likely due to mechanical interference with adjoining structures (lung and mediastinum) and local entrapment or impingement of vessels, tendons or nerves. Rare complication is malignant transformation to chondrosarcoma (1-2%). Most osteochondroma are asymptomatic and does not require any treatment.

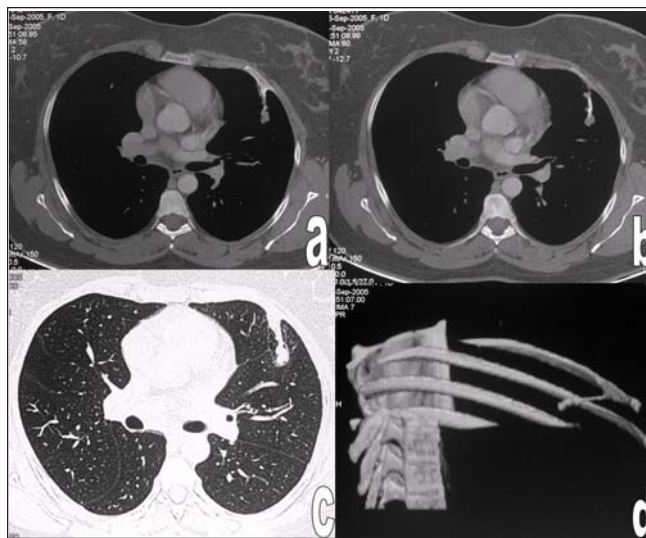


Fig.1 Chest CT & 3-D Bony Reformat Showing Prick Like Inward Projecting Intrathoracic Osteochondroma with Thickened Overlying Pleura

Surgical resection either by thorotomy or video-assisted thoracoscopy is indicated in symptomatic patients (3,4). Even in asymptomatic patients, the resection should be considered in the presence of inward spur.

References

1. Pham-Duc ML, Reix P, Mure PY, Pracros JP, Moreux N, Bellon G. Hemothorax: an unusual complication of costal exostosis. *Journal of Pediatric Surgery* 2005; 40: E55-E57.
2. Hajjar WM, El-Medany YM, Essa MA, Rafay MA, Ashour MH, Al-Kattan KM. Unusual Presentation of Rib Exostosis. *Ann Thorac Surg* 2003;75:575-77
3. Alifano M, Morcos M, Molina T, Regnard JF. An unusual cause of hiccup: costal exostosis. Treatment by video-assisted thoracic surgery. *Eur J Cardiothorac Surg* 2003; 23:1056-58
4. Simansky DA, Paley M, Werczberger A, Ziv YB, Yellin A. Exostosis of a Rib Causing Laceration of the Diaphragm: Diagnosis and Management. *Ann Thorac Surg* 1997; 63:856-57.

From the Department of Radiodiagnosis and Imaging, PGIMER, Chandigarh, India

Correspondence to : Dr Sameer Vyas, Department of Radiodiagnosis and Imaging, PGIMER, Chandigarh, India