



Corneo- Conjunctival Auto Grafting in Pterygium Surgery

Ashok K. Sharma, Vijaya Wali, Archana Pandita

Abstract

To evaluate the efficacy of conjunctival auto grafting in surgical management of primary and recurrent pterygium, the record of 150 patients comprising 47 females and 103 males who underwent corneo-conjunctival auto graft transplant surgery for primary and recurrent pterygia from 1997 to 2003 was reviewed retrospectively. Follow up was done for six months after the surgery. Recurrence of pterygium was considered as failure. All grafts were transplanted promptly. Recurrence was noted in four patients (2.6%). Mild discomfort in the immediate post-operative period was noted in all the patients. Donor site healed without any complication in all the patients. The results indicate that corneo-conjunctival autograft transplantation is an effective treatment for management of both primary & recurrent pterygia.

Key Words

Corneo-conjunctival auto graft, Recurrent pterygium

Introduction

Since the days of Susruta, the world's first ophthalmic surgeon, pterygia have been recognized as triangular sheet of fibro-vascular tissue that appears on the epibulbar conjunctiva and cornea, disturbing both the patient because of their unsightly appearance and the surgeon because of their tendency to recur (1). Pterygia are characterized by excessive fibro-vascular proliferation on the exposed ocular surface and are thought to be caused by increased light exposure, dust, dryness, heat and wind. The pterygium belt extends around the world between the latitudes 35 degree north and 35 degree south of the equator (2). In the exposed population, the growth of pterygia has been seen in younger teenagers and widely prevalent in people in deserts. Pterygia are seen nearly twice as often in men as in women (3).

Successful management of pterygium is a constant challenge for ophthalmologists due to high recurrence

rate (2.1% to 87 %) (4). High recurrence rate and sight threatening complications of different surgical techniques (5) provoke us to look for new and safer modalities of treatment.

The recent concept of the role of the corneal limbal stem cells has led to the development of the new concept of pathogenesis of pterygia. Accordingly pterygium is a local limbal cell deficiency. Pterygium recurrence can be reduced if the limbus and limited area of cornea are included in the conjunctival graft, as it is well recognised that limbal stem cells play a vital role in maintaining the ocular surface. The function of limbal stem cells which are situated in the basal layers of the epithelium include regeneration of the tissue and cell replacement (6, 7). Thoft introduced the concept of ocular surface and idea

From the Postgraduate Department of Ophthalmology, Govt. Medical College, Jammu.

Correspondence to : Dr. Ashok K. Sharma, Cornea Services, Postgraduate Department of Ophthalmology, Govt. Medical College, Jammu.

of its reconstruction (8). This study comprised of the use of corneo-conjunctival autograft transplantation to the pterygia. Conjunctival auto transplant taken from the actinically unexposed conjunctiva prevents proliferation of actinically altered cells into the cornea (9). The present study was undertaken to evaluate the efficacy of corneo-conjunctival autograft in cases of pterygium.

Material and Methods

One hundred and fifty cases of primary or recurrent pterygia were enrolled in the study. The study included 103 males and 47 females with all pterygia being located nasally. The patients presented to the ophthalmologist with varied symptoms as shown in Table 1 and grading of the pterygium was done as shown in Table 2. All cases of atrophic pterygium were excluded from the study. A criterion of encroachment of the cornea by more than 1 mm with active growth was taken for surgical intervention. All the eyes underwent detailed examination in diffuse light and oblique examination using a slit lamp biomicroscope. Pre-operatively all the patients were administered antibiotic and NSAID drops 4-6 times a day for two days. The excision of pterygia was followed by corneo-conjunctival autograft transplantation. All patients were patched for 24 hrs and then examined at weekly interval for four weeks and then monthly thereafter Follow up ranged up to 6 months.

Table 1. Symptoms of Patients.

Irritation, redness, tearing	110
Rapid growth	62
Blurred vision (induced astigmatism)	15
Obstruction of pupillary aperture	12

Table 2. Classification of Pterygia.

Stage I	Minimum invasion, thin translucent growth, thin vessels
Stage II	Moderately thick pannus, deep vessels not visible, significant invasion of cornea
Stage III	Thick fleshy growth covering pupil, dense vascularisation

Surgical technique

The surgical technique involved transferring superficial corneal and limbal tissue with a conjunctival graft of the upper region to the exposed sclera of the same eye after pterygium excision. All the surgeries were performed by the same surgeon (AS).

Peribulbar anaesthesia was administered which consisted 50:50 mixture of 5 ml of 2% lidocaine and 0.5% bupivacaine with 150 units/ml of hyaluronidase. After inserting a lid speculum, the pterygium body including the adjacent tenons capsule was cut, avoiding damage to medial rectus muscle. The pterygium head was peeled off from the cornea. The graft had to be as wide as the area where the pterygium was removed. Then 1cc of BSS was injected subconjunctivally and the bulbar conjunctiva was excised leaving the underlying tenons capsule intact. Once the conjunctival dissection had reached the limbus, the crescent blade was used to dissect part of the superior cornea at the limbus to include limbus, stem cells in the graft. The mono-bloc corneo-conjunctival graft was excised using Vannas scissors. The graft was rotated to the area where pterygium had been removed. The limbal portion of the graft was first secured to the limbus and adjacent- conjunctiva with two 10.0 silk sutures. The conjunctival portion was then anchored to adjacent- conjunctiva using 10.0 silk sutures. The corneal component of the graft was left unsutured. Topical antibiotics were instilled 5-6 times daily for 1 month + NSAID drops. Oral NSAIDs were administered for 5 days to control pain with systemic ciprofloxacin 500 mg×B.D for 5 days. The corneal limbus of the donor site re-epithelized within one week.

During follow up the operated eye was examined under diffuse light and slit lamp and post operative complications were recorded. Recurrence was defined as postoperative regrowth of fibro vascular tissue similar to the original pterygium.

Results

Recurrence during the follow up period was seen in four patients-2.6% (Table 3). All the four patients were

staged as stage II pterygium and were in the age group of 18-40 yrs. Two patients had graft retraction on nasal side and were successfully managed conservatively. One patient had tenon's granuloma which was removed surgically. Graft donor site healed promptly without excessive scarring in all cases. No patient complained of pain during first week after surgery except that they had mild discomfort. In all cases upper lid masked the conjunctival scar. No major complication such as infection, graft necrosis or complications related to anaesthesia occurred in any of the patients.

Table 3. Recurrence of Pterygium.

Case No.	Stage of Pterygium	Age of the patient
1	Stage II	22 yrs.
2	Stage II	18 yrs.
3	Stage II	35 yrs.
4	Stage II	28 yrs.

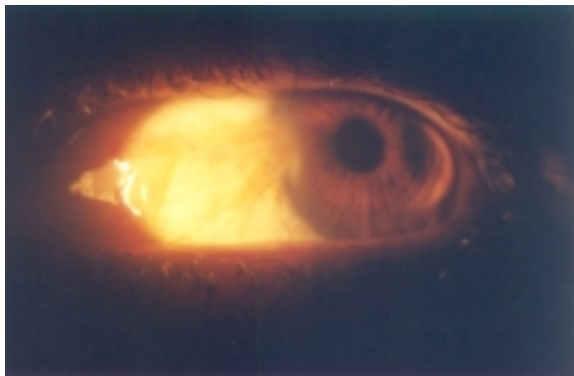


Fig. 1:- Nasal pterygium Stage II.



Fig. 2:- One day post-operative with conjunctival autograft in place.

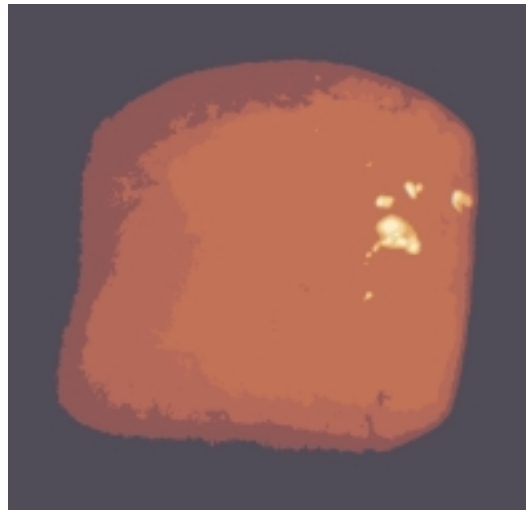


Fig. 3:- Graft donor area on first post-operative day.

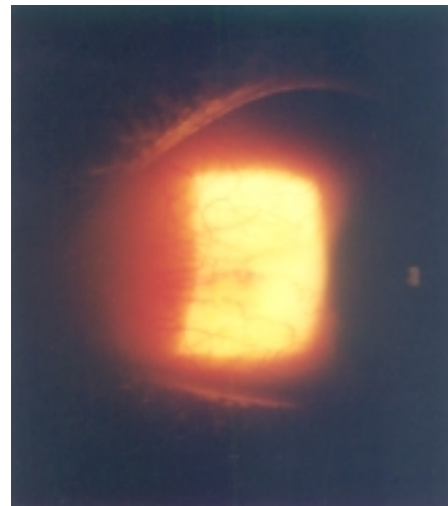


Fig. 4:- No evidence of recurrence six months after conjunctival auto-graft surgery.

Discussion

The main problem encountered after various types of pterygium surgeries is unpredictable rate and timing of recurrence. In this study corneo-conjunctival auto graft transplantation successfully treated 150 eyes with pterygia. The recurrence rate was very low (2.6%) which mean the technique compares favourably with other methods. The recurrence rate with bare sclera techniques is 24% to 89% (10) whereas that reported after conjunctival autograft transplantation ranges from 1.6% to 33% (11).



Adjuvant therapies like β -irradiation, theotepa & mitomycin-C have been proposed to reduce the recurrence but are associated with complications like poor epithelial healing, late onset scleral ulceration, microbial infection, corneal edema, glaucoma & endophthalmitis (12).

Conjunctival autografts were popularised by Kenyon *et al* (13). Conjunctival autografts allow coverage of large defects that occur from large excisions which are often encountered in advanced and recurrent pterygia. A recurrence rate of 21% has been reported by Lewallen *et al* (14). Whereas in our study, the recurrence rate was only 2.6%.

Recurrence of the pterygium is the most dreaded complication. It depends on many factors like type of surgical technique, adequacy of the removal of the pterygium tissue, the age of the patient, size and morphology of the pterygium. Therefore, it is recommended that all pterygium tissue should be identified and excised in toto with appropriate surgical procedure.

The results of the technique used in the present study encourage us to use it more frequently in future as it compares favourably with other techniques.

References

1. Rosenthal JW. Chronology of pterygium therapy. *Am J Ophthalmol* 1953; 36: 1601.
2. Cameron ME. Pterygium throughout the world. In: Thomas C (ed). Springfield, Illinois. 1965; 141-71.

3. Bradley PG, William MT. Pterygium. In: Kaufman (ed) *The Cornea* 2nd ed Butterworth-Hienmann Boston 1998 pp 497-521.
4. Gupta VP. Conjunctival Transplantation for Pterygium. *DJO* 1997; 5: 5-12.
5. Khamar B, Khamar M, Trivrdi N, Vyas U. Pterygium Surgery. In: LC Dutta (ed). *Text book of Ophthalmology*. Edition 2 Part 1, New Delhi 2000 pp 74.
6. Schermer A, Glavin S, Sun TT. Differentiation related expression of a major 64 K corneal keratin in vivo and in culture suggest limbal location of corneal epithelial stem cells. *J Cell Biol* 1986; 103: 49-62.
7. Tsai RJF, SunTT, TsengScg. Comparison of limbal and conjunctival auto graft transplantation in corneal surface reconstruction in rabbits. *Ophthalmol* 1990; 97: 446-55.
8. Thoft RA. Conjunctival transplantation. *Arch Ophthalmol* 1977; 95: 1425-47.
9. Kenyon KR, Wagoner MD, Hettinger ME. Conjunctival auto graft transplantation for advanced and recurrent pterygium. *Ophthalmol* 1985; 92: 1461-70.
10. Duke Elder S. Diseases of the outer Eye. In: Henry Kimpton (ed). *System of Ophthalmology*. Vol 8 Part I. Mosby, London 1965; pp 537-582.
11. Riordan EP, Kielhorn I, Steele ADM. Conjunctival autograft in the surgical management of pterygium. *Eye* 1993; 7: 634-38.
12. Singh G, Wilson MR, Foster CS. Long term follow-up study of mitomycin eye drops as adjunctive treatment for pertygia and its comparison with conjunctival autograft transplantation. *Cornea* 1990; 9: 331-34.
13. Kenyon KR, Wagnor MD. Conjunctival autograph transplantation for advanced and recurrent pterygium. *Ophthalmol*. 1985; 92: 1461.
14. Leewan S. A randomized trial of conjunctival autografting in pterygium in tropics. *Ophthalmol* 1999; 96: 1612.