

# Complications following Use of Intraoperative Mitomycin-C in Pterygium Surgery

Imtiyaz Ahmad, Reyaz Ahmad Untoo, Sheikh Sajjad Ahmad

## Abstract

This study was designed to evaluate the possible complications following the use of intraoperative mitomycin-C in patients undergoing surgery for primary pterygium. Hundred eyes of 88 patients with primary pterygium were operated upon using "bare sclera technique". Intraoperatively all the patients were applied freshly prepared mitomycin-C 0.02% (0.2 mg/ml) on the bare sclera for a period of 5 minutes, after which the eyes were thoroughly rinsed with a sterile balanced salt solution. Postoperatively, none of the patients received mitomycin-C eye drops. After a mean postoperative followup of 14 months, 4 eyes (4%) of 4 patients developed thinning of the sclera with visualization of the underlying uveal tissue. One eye (1%) developed extreme thinning of the sclera with ectasia of the underlying uveal tissue, requiring a scleral patch. Recurrence was seen in 2 eyes (2%) only. The study shows that although intraoperative mitomycin-C (0.02%) reduces the recurrence of pterygium, it leads to serious, cosmetically unacceptable and even sight-threatening complications.

## Key words

Pterygium, Mitomycin-C, Scleral thinning.

## Introduction

Pterygium is a conjunctival degenerative process characterized by a sheet of fibrovascular tissue encroaching upon the cornea within the interpalpebral fissure, almost invariably on the nasal side. Excessive exposure to the ultraviolet sunlight is the most common predisposing factor. Ultraviolet light induced damage to limbal stem cell barrier with subsequent conjunctivalization of the cornea is the current accepted etiology. Other agents that give rise to chronic irritation of the conjunctiva such as air pollution, dust and wind have also been found as determining factors (1).

Treatment of choice for pterygium is surgical excision. However, the recurrence rate is quite high, about 30 -

50%. Various methods have been adopted to reduce the recurrence rate of pterygium after its surgical removal. These include postoperative use of beta - irradiations ; intraoperative or postoperative use of antimetabolic drugs like mitomycin-C, thiotepa etc. Surgical excision with conjunctival autograft and excimer laser phototherapeutic keratectomy. Recently, tranilast, an antiallergic and antiproliferative drug has been studied which inhibited the proliferation and chemotaxis of pterygium - derived fibroblasts and the collagen contraction induced by these cells (2). All these modalities of treatment are however fraught with various mild to severe complications.

**From the Department of Ophthalmology, SKIMS Medical College & Hospital, Bemina, Srinagar (J&K) India.**

**Correspondence to :** Dr. Imtiyaz Ahmad, Department of Ophthalmology, SKIMS Medical College & Hospital, Bemina, Srinagar (J&K) India.

The present study was carried to unveil the complications of mitomycin-C when used intraoperatively in pterygium surgery with an aim to reduce its recurrence rate.

### Material and methods

100 eyes of 88 patients were randomly selected for pterygium surgery. All the pterygia were primary in nature. The patients age varied from 26 - 64 years (average 53 years). out of 88 patients, 52 (59.09%) had only right eye involved ; 24 (27.27%) had involvement of left eye only ; while in 12 (13.63%) patients both eyes were having a primary pterygium. Among the study group, 64 (72.72%) patients were males and 24 (27.27%) patients were females. All the 12 patients with bilateral pterygia were males.

All the surgeries were performed under local anesthesia. The head of the pterygium was grasped with a toothed forceps and excision was begun with No. 15 bard - parker blade about 0.5 mm ahead of the pterygium apex and carried down smoothly to the limbus. The conjunctiva and the subconjunctival tissue were then cleaned over the sclera towards the insertion of the medial rectus muscle and triangular excision of the pterygium and conjunctiva including the tenon's capsule was performed. Haemostasis was achieved with a light thermal ball- point cautery. A sterile sponge (5 x 5 mm) soaked in a sterile container containing freshly prepared mitomycin-C solution 0.02% (0.2 mg/ml) was applied over the bare sclera. After 5 minutes, the sponge was removed and the site was rinsed thoroughly with 10-20 ml of sterile balanced salt solution.

Postoperatively, patients were put on topical steroids for 3-4 weeks. The patients were examined on 1st postoperative day and then after 1 week, 2 weeks, 1 month and later at 2 month intervals for about 12-24 months.

### Results

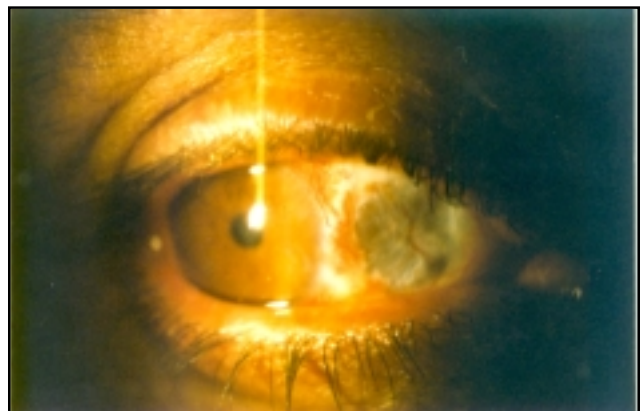
The patients were followed regularly for an average of 14 months (range 12 - 24 months) and the results were analysed.

Twenty six eyes (26%) of 26 patients developed severe photophobia lasting for about 2-3 weeks and was attributed to superficial punctate keratitis.

Four eyes (4%) of 4 patients developed progressive thinning of the bare sclera starting about 4-6 months after surgery. This leads to visualization of the underlying uveal tissue with cosmetically unacceptable appearance. The size of the thinned sclera varied from 2x2 mm to 4x4 mm. In these patients, a fold of conjunctiva was undermined from the adjacent site and sutured at two places over the bare scleral area.

One eye developed extreme thinning of the sclera at the bare area within a period of 3 months and lead to progressive ectasia of the underlying uveal tissue (Fig. 1). To avoid any catastrophe, a thin flap of sclera (about 2x3 mm) was dissected from the superotemporal quadrant of the same eye and sutured over the ectatic tissue. The adjacent conjunctiva was undermined and sutured over the scleral patch. A postoperative followup of 24 months remained uneventful in this patient.

In the study group, 2 eyes (2%) of 2 patients developed recurrence of the pterygium within a period of 4 - 6 months.



**Fig. 1.** Showing ectasia of the underlying uveal tissue due to extreme thinning of the bare scleral area.

## Discussion

Mitomycin-C is an antineoplastic antibiotic produced by streptomyces caesoptoses. It is an extremely toxic, non-cell-specific alkylating agent that selectively inhibits the synthesis of DNA, RNA and protein and prevents cellular division which can lead to cell death. Its cross-linking mode of action produce DNA damage similar to that of ionizing radiation and thus mitomycin-C is being referred to as being radiomimetic. Treated sclera may become white or "porcelanized" due to destroyed vessels and remain so for ever. Rubinfeld *et. al.* hypothesized that this is due to the drugs effect on multipotential cells and the rapidly proleferating cells of vascular endothelium (3).

A long term followup to monitor for complications is necessary in mitomycin-C treated eyes. Various complications reported after mitomycin-C use include : irritation, photophobia, delayed epithelial healing, avascularity of the sclera, scleral calcification (4), scleral ulceration (5), necrotizing scleritis (6), perforation, iridocyclitis, cataracts, punctal occlusion, infection, glaucoma, symblepharon formation (7) and even loss of vision.

Several case reports have concluded that patients with conditions predisposed to ulceration or poor wound healing such as Sjogren's syndrome, severe keratoconjunctivitis sicca, severe meibomian gland dysfunction, blepharitis, acne rosacea, atopic keratoconjunctivis, uveitis, neurotropic keratitis or herpes simplex keratitis should not be considered for mitomycin-C therapy (8).

Some authors have proposed the use of very low dose mitomycin-C (0.01%) after pterygium excision (9) and few studies which compared use of mitomycin-C in different concentrations have shown promising results with use of low dose mitomycin-C (0.03%).

Only 2 (2%) recurrences were reported in our study and the recurrences occured within first 6 months. Our

data confirm those of Hirst et al (10) who affirm that a 12 month followup is able to identify more than 97% of recurrences.

## Conclusion

Although mitomycin-C used intraoperatively in a concentration of 0.02% (0.2 mg/ml) for 5 minutes has grossly reduced the recurrence rate, but leads to severe postoperative complications, which could be even sight-threatening. Thus we recommend that mitomycin-C when used intraoperatively should be of the lowest concentration (0.02%) and that the exposure time should be reduced to less than 5 minutes.

## References

1. Pico G, Smith J. Eye diseases in hot climates. *Bristol ELBS Wright* 1987 ; 104-05.
2. Isaji M, Kikuchi S, Miyata H *et. al.* Inhibitory effects of tranilast on the proliferation and functions of human pterygium - derived fibroblasts. *Cornea* 2000 ; 19 (3) : 364-68.
3. Rubinfeld RS, Pfister PR, Stein RM *et. al.* Severe complications of topical mitomycin-C after pterygium surgery. *Ophthalmology* 1992 ; 99 : 1647-54.
4. Gupta S, Basti S. Corneoscleral, ciliary body and vitreoretinal toxicity after excessive instillation of mitomycin-C. *Am J Ophthalmol* 1992 ; 114 : 503-04.
5. Dunn JP, Seamone CD, Ostler HB *et. al.* Development of scleral ulceration and calcification after pterygium excision and mitomycin-C therapy. *Am J Ophthalmol* 1991 ; 112 : 343-44.
6. Dougherty PJ, Hardten DR, Lindstorm RC. Corneoscleral melt after pterygium surgery using a single application of mitomycin-C. *Cornea* 1996 ; 15 : 537-40.
7. Hayasaka S, Noda SN, Yamamoto Y *et. al.* Postoperative instillation of low dose mitomycin-C in the treatment of primary pterygium. *Am J Ophthalmol* 1988 ; 106 : 715-18.
8. Sugar A. Who should recieve mitomycin-C after pterygium surgery. *Ophthalmology* 1992 ; 99 : 1645-46.
9. Frucht-pery J, Iisar M. The use of low dose mitomycin-C for prevention of recurrent pterygium. *Ophthalmology* 1994 ; 101 : 759-62.
10. Hirst LW, Sebban A, Chant D. Pterygium recurrence time. *Ophthalmology* 1994 ; 101 : 755-58.