

## Synchronous Urolithiasis in Orthotopic and Left to Right Crossed Ectopic Kidneys, without Fusion, presenting as Acute on Chronic Renal Failure

P. N. DOGRA, MS, MCh

### Abstract

Presented here is a case of 20 year old male with multiple calculi in orthotopic as well as in left to right crossed ectopic kidney without fusion, causing obstructive uropathy, leading to progressive renal failure and uraemia, thus posing a challenge in management. After pre-operative preparation with repeated haemodialysis, a complete clearance of stones from both kidneys was accomplished at one operation. The post-operative course was uneventful with considerable improvement and stabilization in renal functional status.

### Key words

Ectopic kidneys, Urolithiasis, Chronic renal failure.

### Introduction

Crossed renal ectopia is not an uncommon urological condition. Ninety percent of crossed ectopic kidneys are fused to their ipsilateral mates and in only 10% of cases, they remain unfused. The patient presented herein belonged to the latter group of crossed ectopia with stones in both the renal units. This rare presentation, posed us a special challenge in management. The use of intra-operative contact organ radiography and nephroscopy is emphasized.

### Case Report

A 20 year old male was admitted in the Urology Emergency at our institute with a mass in the abdomen, vague abdominal pain, generalised weakness, diminished

urine output, loss of appetite, vomiting and puffiness of face setting in over 2-3 years duration.

**On Examination :** He was ill-looking and showed facial oedema, Pulse : 80/min, regular; B. P. = 170/110 mm. Hg.

There was a large 10" × 3", intra-abdominal mass extending from the right hypochondrium to the corresponding iliac fossa, it was non tender and firm in consistency.

**Investigations :** Hb-7.4 gm%, blood urea : 300 mg%, serum creatinine : 14.6 mg%, serum electrolytes including calculous disease parameters were normal and

From the Department of Urology, A.I.I.M.S., New Delhi-110029.

Correspondence to : Dr. P. N. Dogra, Additional Professor Department of Urology A. I. I. M. S., New Delhi-110 029

24 hour urinary biochemical parameters were within normal range in low urine volume. Urine culture was sterile. The creatinine clearance was 7.3 ml/min. KUB revealed multiple radio-opaque densities on right side of abdomen arranged in 2 groups, over renal area and iliac regions. (Fig 1).

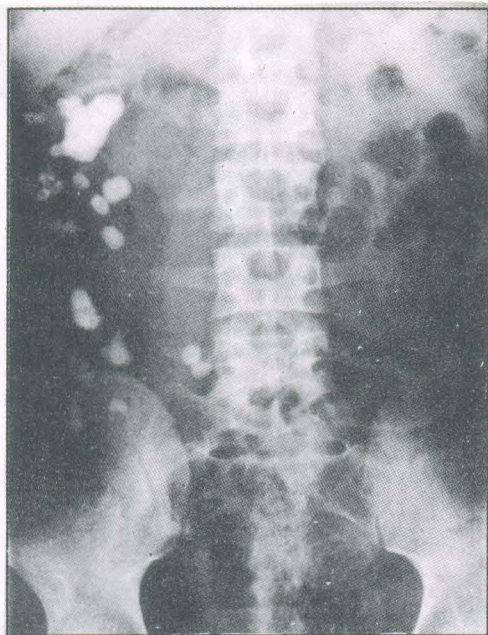


Fig. 1. KUB showing multiple calculi on right side arranged in two groups.

**Abdominal Ultrasonography :** Right kidney grossly hydronephrotic extending from right hypochondrium to iliac fossa and containing echogenic masses suggestive of calculi. No kidney tissue seen on left side.

**High-dose Urography :** No contrast effect in renal areas, even after 36 hours.

**Renal Scan (G. H. A.) :** Poor renal uptake of radionuclide, left kidney ectopically situated below right kidney.

After these investigations, an impression of left to right crossed renal ectopia with multiple stones and acute on chronic renal failure was made.

Pre-operative preparation included repeated haemodialysis, blood transfusions and control of hypertension.

**Angiography :** was avoided due to extreme renal insufficiency.

The **surgical procedure** executed was bilateral retrograde pyeloureterography (RGP) which confirmed the diagnosis (Fig. 2). Complete clearance of stones from both kidneys by pyelolithotomies aided by multiple nephrotomies was achieved using intra-operative contact organ roentgenography and nephroscopy. The upper pole of the left kidney was adherent to the lower pole of right kidney, but not fused.

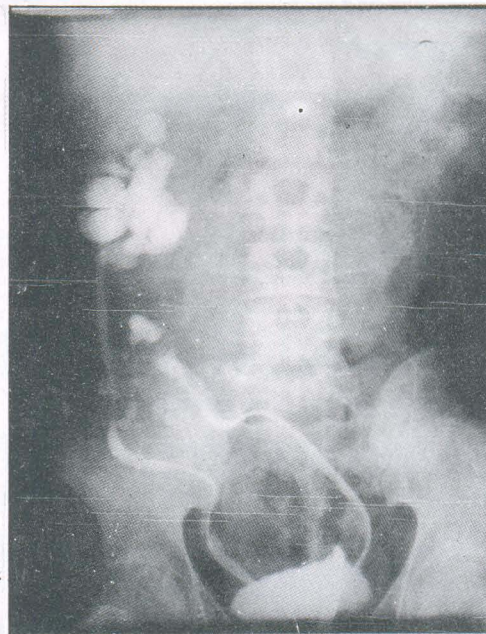


Fig. 2. B/L RGP showing both kidneys on right side.

Post-operatively the patient has shown remarkable improvement and stability in renal functional status in one year of follow up period. (Blood urea : 80 mg %, serum creatinine : 6.2 mg %, creatinine clearance : 17 ml/min).

## DISCUSSION

The first reported case of crossed renal ectopia was described by Pamarolus in 1654.

A significant review of the subject was conducted by Abeshouse and Bhisitkul (1) in 1959, who collected exactly 500 cases of crossed renal ectopia with and without fusion. Numerous case reports have since been published.

Ninety percent of the crossed ectopic kidneys are fused to their ipsilateral mates on one side. Only 10% of crossed ectopic kidneys occur without fusion (2). The case presented herein belongs to this very small uncommon group of anomalies.

Crossed ectopic kidneys are neither immune nor susceptible to the common diseases which effect the otherwise normally situated kidneys, but they are at higher risk for developing urinary tract infection, renal calculus or both. Calculus formation in one or the other

usually ectopic kidney (3), is well known but the simultaneous occurrence of bilateral multiple calculi in such an anomalous situation leading to acute on chronic renal failure has not been published in the literature to the best of my knowledge. The common mode of presentation of such cases have been with symptoms and signs pertaining to unilateral underlying disease i. e. urinary infection, renal calculus or hydronephrosis (4).

## References

1. Abeshouse BS and Bhisitkul I. Crossed renal ectopia with and without fusion. *Urol Int* 1959 ; 9 : 63.
2. Winram RG and Ward-McQuaid JN. Crossed renal ectopia without fusion. *Canad Med Assoc J* 1959 ; 81 : 481.
3. Stubbs AJ and Resnick MI. Struvite staghorn calculi in crossed renal ectopia. *J Urol* 1977 ; 118 : 369
4. Boatman DL, Culp DA Jr., Culp DA and Flocks RH. Crossed renal ectopia. *J Urol* 1972 ; 108 : 30.



### CONFERENCE ANNOUNCEMENT

INTERNATIONAL CONFERENCE

ON

“RECENT ADVANCES IN MEDICINE—AN UPDATE”

Under the Auspices of

Govt. Medical College, Srinagar, J&K

MCI and American College of Physicians (ACP-ASIM)

August 21-22, 1999

Sher-i-Kashmir International Convention

Complex (Centuar Hotel) Srinagar

**Organising Secretary : Dr. G. M. Malik, M.D, FACC**

P. O. Box No. 884 GPO Srinagar-190 001 Kashmir (India)