



## CASE REPORT

## Multiple Enchondromatosis: Ollier's Disease

Feroze Shaheen, Nisar Ahmad, Tariq Gojwari, M. Ashraf Teli \*, Riyaz Resold, Manjeet Singh

### Abstract

Multiple enchondromatosis (Ollier's disease) is a rare disease characterized by widespread enchondromas with a unilateral predominance, especially in fingers in early childhood. In general, the short tubular bones of the hand are involved, with progressive lesions resulting in cosmetic problems and functional deformities. Herein, we, describe two cases of Ollier's disease diagnosed on X-ray of hands followed by MRI. There was no evidence of cortical disruption or periosteal reaction associated in either case. The bone lesions revealed cartilaginous matrix. MRI using conventional T1W and T2W sequences and STIR showed expansile lesions within the metacarpals and phalanges of both hands with cartilaginous matrix.

### Key Words

Enchondromatosis, Olliers Disease

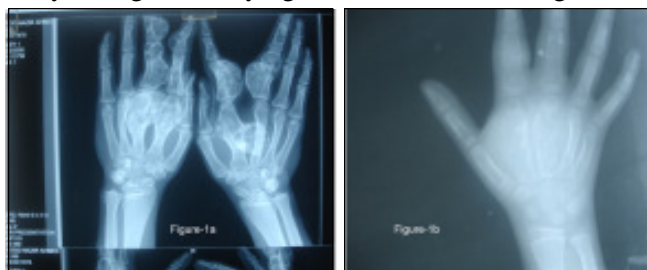### Introduction

Enchondromas are common intraosseous, usually benign cartilaginous tumors, which develop in close proximity to growth plate cartilage. When multiple enchondromas are present, the condition is called enchondromatosis also known as Ollier's Disease (WHO terminology). The estimated prevalence of Ollier's disease is 1/100,000 (1,2). Clinical manifestations often appear in the first decade of life. Ollier's disease is characterized by an asymmetric distribution of cartilage lesions and these can be extremely variable (in terms of size, number, location, evolution of enchondromas, age of onset and of diagnosis, requirement for surgery). Clinical problems caused by enchondromas include skeletal deformities, limb-length discrepancy, and the potential risk for malignant change to chondrosarcoma. The condition in which multiple enchondromatosis is associated with soft tissue hemangiomas is known as Maffucci syndrome. The diagnosis is based on clinical and conventional radiological evaluations. Histological analysis has a limited role and is mainly used if malignancy is suspected. There is no medical treatment for enchondromatosis. Surgery is indicated in case of complications (pathological fractures, growth defect, and malignant transformation). The prognosis for Ollier's disease is difficult to assess.

As is generally the case, forms with an early onset appear more severe. Enchondromas in Ollier disease present a risk of malignant transformation of enchondromas into chondrosarcomas.

### Case Reports

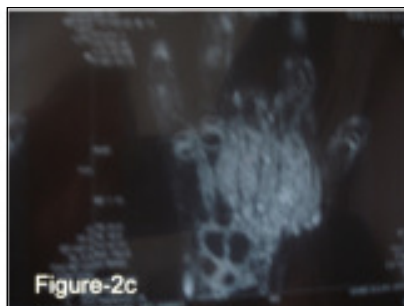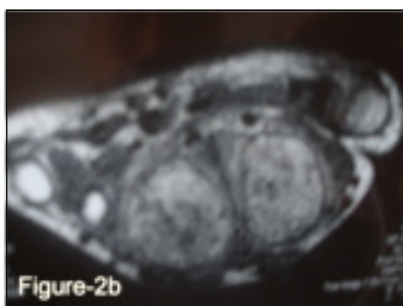
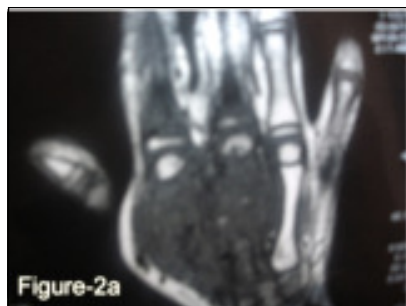First case was a fifteen year old male patient presenting with a long history of multiple swellings in hands. These started some ten years before and progressed slowly. Swellings were painless and he did not complain of any other swelling anywhere in the body. There was no such history in his family. On examination multiple discrete, hard swellings were palpable in hands appearing to be bony in origin. Overlying skin was normal; no significant



**Fig.1a & b: Plain X-Ray in 1<sup>st</sup> Patient Showing Central Geographic Expansile Bone Lesions in Tubular Bones of Both Hands & in 2<sup>nd</sup> Patient Showing Expansile Bone Lesions in Short Tubular Bones of Hand with Mineralized Matrix**

From the Department of Radio diagnosis and Imaging & \*Department of Radiation Oncology, SKIMS, Srinagar-India

Correspondence to : Dr.Feroze Shaheen, Associate Prof, Dept. of Radiodiagnosis & Imaging, SKIMS, Srinagar, Kashmir, India 190011



**Fig.2a, b & c: Coronal T1W MRI Showing the Bone Lesions Isointense with Muscles. Axial T2W MRI Depicting Hyperintense Bone Lesions. Coronal STIR Showing the Expansile Hyperintense Bone Lesions Without Cortical Disruption**

discrepancy in size between two upper limbs was appreciable. X-ray of hands was ordered which showed multiple central geographic lytic lesions in the tubular bones of metacarpals and phalanges in both the hands. The lesions were asymmetrically distributed (*Fig.1a*). Lesions were intramedullary and caused expansion of involved bones with scalloping of inner cortex. Small foci of calcifications were present in the lucencies. No cortical destruction was seen, no soft tissue component was seen around the bones. Carpal bones were spared; no definite lytic lesion was seen in the feet, legs, thighs, arms, pelvic or shoulder girdles. A diagnosis of Multiple enchondromatosis (Ollier's disease) was made based on the morphology and location of bone lesions on plain radiographs. Second case was 7 year old girl with two year history of swelling of hand bones on one side. Plain X-ray showed expansile bony lesions in metacarpal bones with lobulated contour and mineralized matrix. No cortical disruption was seen (*Fig.1b*). MRI in both cases showed homogenous high signal in a discernable lobular configuration on T2W SE images. T1W SE images showed lobulated intramedullary lesions with signal intensity approximating that of skeletal muscle (*Fig.2a,b&c*).

**Discussion**

Enchondromatosis, or multiple enchondromas, occur in three distinct different conditions (1, 2). The most common entity is Ollier's disease, a non-hereditary failure of cartilage ossification, resulting in multiple enchondromas that typically affect the metaphyseal ends of bones (3). It usually becomes evident before puberty and is unilateral, leading to shortening of the limbs (1). The lesions enlarge with progressive skeletal growth, becoming more evident and characteristic with time. After the cessation of normal growth, the lesions do not increase in size. The lesions cause enlargement, shortening and

bowing of the bones (4). The incidence of malignant transformation has been reported to be approximately 30%-50%. (5). Maffucci syndrome is also a non-hereditary syndrome that is rarer than Ollier disease (6). It is characterized by multiple enchondromatosis as well as multiple soft tissue cavernous haemangiomas, and less commonly lymphangiomas (1). There is also a higher risk of malignant transformation of enchondromas to sarcomas (5). Both Maffucci syndrome and Ollier's disease are associated with an increased incidence of malignancies other than musculoskeletal malignancies, including gliomas, gastrointestinal adenocarcinoma, pancreatic carcinomas and ovarian tumor (7, 8). The third condition, metachondromatosis, is a hereditary autosomal dominant transmitted trait consisting of multiple enchondromas and osteochondromas (1). In this distinct syndrome, the multiple exostoses characteristically occur in the digits and long bones, and unlike those in hereditary multiple exostoses, point towards the joints and frequently regress spontaneously. All these three conditions are characterized by multiple enchondromas or enchondromatosis (2, 9). Enchondromas are hypothesized to develop from rests of growth plate cartilage that subsequently proliferate and slowly enlarge (4). Therefore, any bone formed by enchondral ossification may be affected.

Clinical manifestations in Ollier's disease often appear in the first decade of life and usually start with the appearance of palpable bony masses on a finger or a toe (9). Upon physical examination, enchondromas present on the extremities are usually visible as masses embedded within phalanges, metacarpal and metatarsal bones. The lesions may affect multiple bones and are usually asymmetrically distributed, exclusively or predominantly



affecting one side of the body (4). Affected bones are often shortened and deformed. Indeed, bone shortening may be the only clinical sign of the disease. In childhood, the lesions are subjected to pathologic fractures (9).

Roentgenograms typically show multiple, radiolucent, homogenous lesions with an oval or elongated shape and well defined slightly thickened bony margin. The lesions and long bone axis run parallel. The lesions usually calcify with time and become diffusely punctated or stippled. Enchondromas are frequently assembled as clusters, thus resulting in the metaphyseal widening. Enchondromas are almost exclusively localized in the metaphysis of long bones and in the small bones of the hands and feet (4). They are initially localized close to the growth plate cartilage and then migrate progressively towards the diaphysis.

Again, it is important to emphasize the irregular distribution of the lesions. If lesions are distributed over the entire body, one side is typically more affected. In the hands, the lesions almost never affect all metacarpal bones and phalanges (1, 9).

Enchondromas result in severe growth abnormalities. Affected diaphyses are short and massively enlarged, and these may show bending close to the metaphysis. Ulnar shortening is usually more relevant than shortening of the radius; fingers often show irregular sizes. Signs of pathological fractures may be present (3, 9).

Signs of malignant transformation should be looked for, as it is a major complication of enchondromatosis. These signs include cortical erosion, extension of the tumor into soft tissues, and irregularity or indistinctness of the surface of the tumor (5, 6).

The diagnosis of Ollier's disease is based on clinical and conventional radiological evaluations. Histological analysis has a limited role and is mainly used if malignancy is suspected. Additional investigations, such as scintigraphy, ultrasound, and magnetic resonance imaging (MRI) are not useful for establishing the diagnosis. They are indicated for the evaluation and surveillance of lesions that become symptomatic (pain, increase in size).

Ollier's disease must be differentiated from hereditary multiple exostoses (HME). The most important criterion to distinguish enchondromas from osteochondromas as seen in HME is the localization of bone lesions: osteochondromas are located at the bone surface and enchondromas are located in the center of bones, thus allowing radiographic distinction (1, 4).

There is no medical treatment for Ollier's disease. Ollier's disease is usually surgically treated, considering the high frequency of malignant evolution of the lesions even though tumors are often benign (10). In case of malignant evolution radiotherapy and/or chemotherapy are requested (10). Relapses are frequent (25-50%).

The prognosis of Ollier's disease is difficult to assess. As is generally the case, forms with an early onset appear more severe. Enchondromas in Ollier's disease present a risk of malignant transformation of enchondromas into chondrosarcomas, which usually occurs in young adults, and thus at an earlier age than observed in patients with chondrosarcoma alone (5). The reported incidence of malignant transformation is variable & estimated to occur in 5-50% of the cases (1, 5). It is higher in Maffucci's syndrome, the prognosis of which is more severe than that of Ollier disease (6). Association of Ollier's disease with other tumors has also been reported (7, 8).

#### References

1. Khoo RN, Peh WC, Guglielmi G. Clinics in diagnostic imaging (124). Multiple enchondromatosis in Ollier disease. *Singapore Med J* 2008; 49(10):841-45
2. Spranger J, Kemperdieck H, Bakowski H, Opitz JM. Two peculiar types of enchondromatosis. *Pediatr Radiol* 1978; 7(4): 215-19
3. Silve C, Jüppner H. Ollier disease. *Orphanet J Rare Dis* 2006 22; 1:37
4. Whyte M. Acquired Disorders of Cartilage and Bone. American Society for Bone and Mineral Research; Washington DC: 2003
5. Schwartz HS, Zimmerman NB, Simon MA, Wroble RR, Millar EA, Bonfiglio M. The malignant potential of enchondromatosis. *J Bone Joint Surg Am* 1987; 69 (2): 269-74
6. Flach HZ, Ginai AZ, Oosterhuis JW. Maffucci syndrome, radiologic and pathologic findings. *Radiographics* 2001; 21: 1311-16
7. Tamimi HK, Bolen JW. Enchondromatosis (Ollier's disease) and ovarian juvenile granulosa cell tumor. *Cancer* 1984; 53:1605-08
8. Mahafza WS. Multiple enchondromatosis Ollier's disease with two primary brain tumors. *Saudi Med J* 2004; 25:1261-63
9. Schwarz W, Harges J, Schulte M. Multiple enchondromatosis: Ollier's disease. *Unfallchirurg* 2002; 105 (12): 1139-42
10. Bulent Erol, Cihangir Tet K, Evrim R N, Bar Kocao LU, Murat B. Surgical treatment of hand deformities in multiple enchondromatosis: a case report. *Acta Orthop Traumatol Turc* 2006; 40(1):89-93