



Radiological Manifestations of Scrub Typhus

Manjot Kaur*, Rakendra Singh

Introduction

Scrub typhus is a potentially fatal infectious disease caused by the organism *Orientia tsutsugamushi*. It may clinically present as acute flu like syndrome, hepatic dysfunction, pulmonary involvement, cardiovascular, renal dysfunction, aseptic meningitis and multiorgan involvement. A high degree of clinical suspicion and knowledge of the various radiologic manifestations of scrub typhus allow an early diagnosis and timely initiation of appropriate therapy, and thereby may help reduce patient morbidity and mortality. The radiologic findings of scrub typhus are varied and nonspecific (1). Nevertheless, an awareness of the related findings at imaging (X-ray, ultrasound, MRI & especially computed tomography (CT)) may facilitate accurate diagnosis.

Pulmonary Findings

The reported incidence of chest radiographic abnormalities in patients with scrub typhus varies from 59% to 72% (1, 2). The pulmonary manifestations of scrub typhus include interstitial pneumonia, interstitial edema, and hemorrhage caused by vasculitis. Interstitial pneumonia (IP) frequently occurs in patients with scrub typhus and is closely associated with severity of the disease. The recognition of the presence of Interstitial Pneumonia is an important determining factor for predicting the clinical course and prognosis for patients with scrub typhus.

Bilateral diffuse areas of reticulonodular opacity (Fig-1) and septal lines are the most common findings (1, 2). Airspace consolidation is relatively uncommon and generally appears in the lower zone of both lungs (1, 2). Unilateral or bilateral hilar enlargement and pleural effusion are common radiographic features, found in 25%-27% and 12%-43% of patients, respectively (1, 2).

Ground-glass opacity, interlobular septal thickening and pleural effusions are common findings at thin-section CT (Fig-2), whereas bronchial wall thickening, centrilobular nodules and axial interstitial thickening are less common.

Contrast-enhanced chest CT images in most cases depict mediastinal and axillary lymphadenopathy (short axis diameter of more than 10 mm). A very serious complication of scrub typhus is acute respiratory distress syndrome

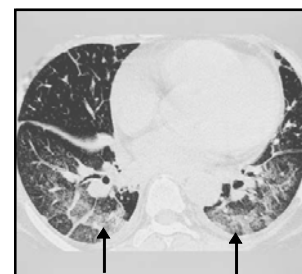
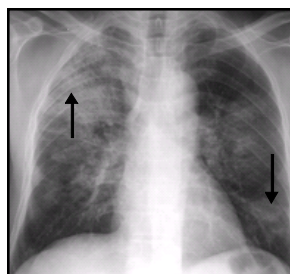


Fig 1&2. Chest Radiograph in a Scrub Typhus Patient Shows Multiple Foci of Reticular & Patchy Opacities in Both Lung Fields. HRCT of Lower Lung Zones Shows Interlobular Septal Thickening, Bronchial Wall Thickening, Diffuse Ground Glass Opacities (arrows) in the Dependent Lung Zones, Increased Vascular Diameter, Mild Cardiomegaly, Bilateral Pleural Effusions and Subsegmental Atelectasis.

(Fig-3). It is rare and may occur in older age group patients with thrombocytopenia, and presents with radiographic evidence of early pneumonitis (3).

Cardiac Findings

Myocardial lesions were observed in 80% of patients in one autopsy series (4). Interstitial myocarditis may occur in scrub typhus. Cardiomegaly, which may be due to myocardial or pericardial involvement in the infection (5-7), is usually reversible (1). Congestive cardiac failure is

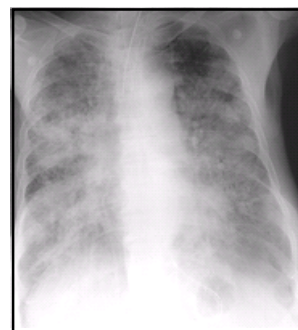

Fig 3. Diffuse Confluent Air-Space Opacities Involving Both Lungs & Normal Heart Size Compatible With Radiologic Features of Acute Respiratory Distress Syndrome

From the Deptt. of *Radiodiagnosis & Medicine, Adesh Inst. of Medical Sciences & Research, Bathinda, Punjab-India

Correspondence to : Dr Manjot Kaur, Asstt. Prof., Deptt. of Radiodiagnosis, Adesh Inst. of Medical Sciences & Research, Bathinda, Punjab.

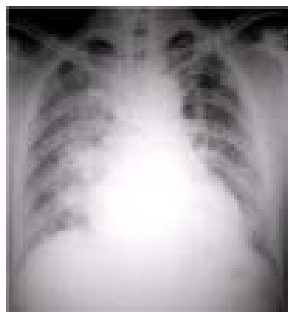

Fig 4. Chest Radiograph Shows Cardiomegaly & CHF
 another cardiac complication. Mixed pulmonary and cardiovascular involvement may be seen as-

- Reticular infiltration and cardiomegaly
- Reticular infiltration and congestive heart failure
- Reticular infiltration, plus air space nodules and cardiomegaly/congestive heart failure
- Cardiomegaly or congestive heart failure (CHF) plus air space nodules (Fig-4)

Abdomino-Pelvic Findings

Abdominal involvement is not uncommon in patients with scrub typhus. Radiographic findings of abdomen may be periportal areas of low attenuation in the liver, GB wall thickening, pericholecystic edema (Fig-5&6), splenomegaly, splenic infarcts and enlarged lymph nodes. The hepatic congestion and periportal inflammation that frequently occur in scrub typhus may cause relative obstruction of the hepatic vein outflow as well as compression of the portal vein with dilatation of the peribiliary plexus (8). Because of these hemodynamic changes, hepatic arterial flow may be increased and inhomogeneous early phase enhancement therefore may occur (8). This appearance of the liver at dynamic contrast-enhanced CT in patients with scrub typhus is similar to the pattern noted in other liver diseases like liver cirrhosis, Budd-Chiari syndrome, hepatic congestion, acute cholangitis/cholecystitis & abscess.

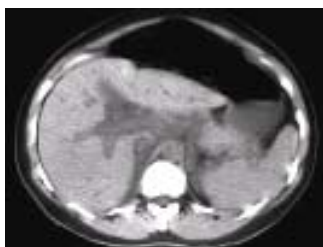

Fig 5. Unenhanced CT image of the Liver Demonstrates Periportal Edema (arrow) and Fluid in Morison's Pouch

Central Nervous System Findings

Meningo-encephalitis of varying severity is seen in scrub typhus patients. Although central nervous system

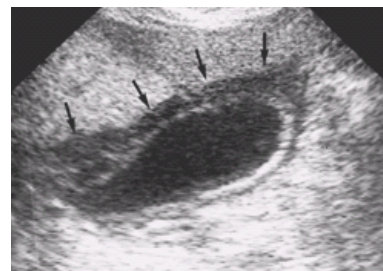

Fig 6. Longitudinal U/S Showing Gall Bladder Wall Thickening

involvement is common in scrub typhus (9,10), only one case report of typhus encephalomyelitis diagnosed at brain MR imaging has been published in the English-language literature, to our knowledge. In this case, the T2-weighted images depicted areas of signal hyperintensity in the dorsolateral pontomedullary region, bilaterally in the cerebellar peduncles, and in the cervical spinal cord (11).

Conclusion

Hence, radiological investigations can help a clinician in predicting the clinical course and prognosis for patients with scrub typhus.

References

1. Choi YH, Kim SJ, Lee JY, *et al.* Scrub typhus: radiological and clinical findings. *Clin Radiol* 2000; 55: 140-144.
2. Song SW, Kim KT, Ku YM, *et al.* Clinical role of interstitial pneumonia in patients with scrub typhus: a possible marker of disease severity. *J Korean Med Sci* 2004; 19: 668-73.
3. Tsay RW, Chang FY. Acute respiratory distress syndrome in scrub typhus. *QJM* 2002; 95: 126-28.
4. Levine HD. Pathologic study of thirty-one cases of scrub typhus fever with especial reference to the cardiovascular system. *Am Heart J* 1946; 31: 314-28.
5. Yotsukura M, Aoki N, Fukuzumi N, Ishikawa K. Review of a case of tsutsugamushi disease showing myocarditis and confirmation of Rickettsia by endomyocardial biopsy. *Jpn Circ J* 1991; 55: 149-53.
6. JeongMH, Ahn YK, Gill GC, *et al.* Tsutsugamushi myocarditis with congestive heart failure and persistent atrial standstill. *Jpn Circ J* 1996; 60: 382-88.
7. ChangJH, Ju MS, Chang JE, *et al.* Pericarditis due to tsutsugamushi disease. *Scand J Infect Dis* 2000; 32: 101-02.
8. AraiK, Kawai K, Kohda W, *et al.* Dynamic CT of acute cholangitis: early inhomogeneous enhancement of the liver. *AJR Am J Roentgenol* 2003; 181: 115-18.
9. SilpapojakulK, Ukkachoke C, Krisanapan S, Silpapojakul K. Rickettsial meningitis and encephalitis. *Arch Intern Med* 1991; 151: 1753-57.
10. PaiH, Sohn S, Seong Y, *et al.* Central nervous system involvement in patients with scrub typhus. *Clin Infect Dis* 1997; 24: 436-40.
11. KimDE, Lee SH, Park KI, Chang KH, Roh JK. Scrub typhus encephalomyelitis with prominent focal neurologic signs. *Arch Neurol* 2000; 57: 1770-72.