

Sturge Weber Disease in a Child

Ravinder K. Gupta, Arjun Singh

Abstract

Sturge Weber Disease is one of the important neurocutaneous syndrome characterized by abnormalities of both the integument and central nervous system. We present here a classical case of Sturge Weber Disease. This 16 month male child had facial angioma and seizures. CT Scan head was consistent with the diagnosis.

Key words

Sturge Weber Disease, Seizures, Facial Angioma.

Introduction

Sturge Weber Disease (SWD) consists of constellation of symptoms and signs including a facial nevus (Portwine stain, congenital facial angioma), seizures, hemiparesis, intracranial calcifications and in many cases, mental retardation. It occurs sporadically, with a frequency of approximately 1/50,000 (1-5). The facial angioma is usually unilateral but may bilateral. It typically involves at least the upper face, superior eyelid, or periorbital region. Angiomas also can be located in other areas of head, including the nasopharynx, palate, lips, gingival and tongue as well the neck, trunk and limbs. The facial angioma conforms to sensory distribution of the trigeminal nerve, which may be determined by embryologic facial development (1,2). We present here a child who had classical features of SWD

Case Report

A 16 month old male child who presented with facial nevi which was involving upper face on right side since birth which was progressively increasing. The hemangioma extended upto periorbital region and forehead. On detailed history child did have episodes of abnormal movements of body. These seizures started on leg and half of the body and later involved whole of the body. The seizures were followed by loss of consciousness. There was no history of trauma, fever, ear discharge, vomiting, loose motions, bleeding from any site etc. The child did not have any symptoms pertaining to heart, kidneys, eyes and lungs. The milestones were consistent with age. It was a home

delivery born after consanguineous marriage. Antenatal and perinatal history was uneventful. On detailed examination, the child was well built (weight - 10 kg and height - 76 cm) with mild pallor. The child did have facial hemangioma on right side which involved periorbital region and superior eye lid. (Fig. 1)

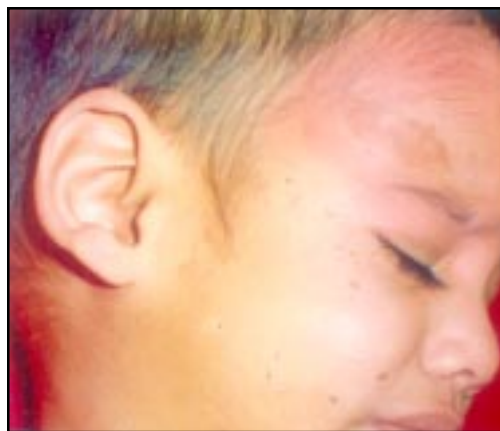

Fig. 1. Showing facial hemangioma right side involving periorbital region and superior eyelid.

Detailed systemic examination including eye and fundus examination did not reveal any abnormality. The hemoglobin was 10gm /dl, liver function, renal function tests, blood sugar, calcium were within normal limits. Xray skull was normal. CT scan of head did reveal calcification and atrophy of right cerebral hemisphere (Fig. 2). EEG was abnormal in this child. In view of clinical details, CT Scan and EEG,

From the Department of Pediatrics Acharya Sri Chandra College of Medical Sciences & Hospital, Sidhra, Jammu.

Correspondence to : Dr. Ravinder K. Gupta, 209A, The Nest, Gandhi Nagar, Jammu.



the child was diagnosed as a case of SWD. He was managed symptomatically.

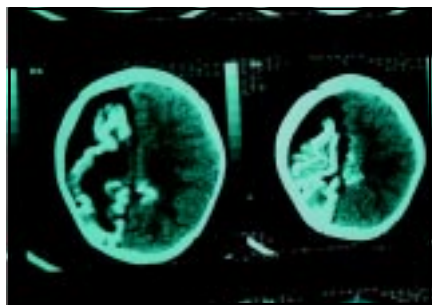


Fig. 2. CT Scan head showing right sided calcification and cerebral atrophy

Discussion

The Sturge Weber Disease is thought to result from anomalous development of the primordial vascular bed during the early stages of cerebral vascularization. At this stage, the blood supply to the brain, meninges, and face is undergoing reorganization while the primitive ectoderm in the region differentiates into the skin of the upper face and occipital lobe of the cerebrum. The overlying leptomeninges are richly vascularized, and the brain beneath becomes atrophic and calcified, particularly in the molecular layer of the cortex, in patients with SWD (1,2). The facial nevus is present at birth. Our child too had facial angioma in right side of upper face including periorbital region.

Buophthalmos and glaucoma of the ipsilateral eye are a common complication (1). The detailed eye examination in our child did not reveal anything abnormal. Seizures develop in most patients during first year of life. They are typically focal tonic-clonic and contralateral to the side of the facial nevus (1-5). Our child had partial seizure on left side with secondary generalization. In one of the retrospective study out of 102 patients with SWD, 88 had unihemispheric involvement whereas 14 had bihemispheric involvement (2). The seizures in SWD may become refractory to anticonvulsants and are associated with a slowly progressive hemiparesis in many cases (1).

About one half of patients are mentally abnormal and have behavioral problems. As seizures of early onset increase in frequency and severity, mental functions and behaviour often regress probably the result of prolonged generalized seizures and increasing cerebral atrophy

secondary to local hypoxia and use of numerous anticonvulsants (1,2). The milestones in our child were consistent with age. Hemisensory defects may occur but often are difficult to document in young and mentally subnormal children (3).

Plain skull radiographs usually demonstrate intracranial calcification that have a serpentine linear, parallel configuration (tram sign) primarily in the occipital or parieto-occipital regions in about 90% of patients. Our child's skull radiograph was normal. This probably was because the changes appear usually by the second decade. CT Scan brain highlights the extent of calcification that is usually associated with unilateral cortical atrophy and ipsilateral dilatation of lateral ventricle. The findings in our child were almost similar (fig 2). The child was managed symptomatically. He was prescribed sodium valproate and nutritional rehabilitation was done. Seizures were controlled after a 3 months follow up. The facial nevus as often is a target for ridicule by classmates, leading to psychologic trauma. Flash lamp - pulsed laser therapy holds considerable promise for clearing the portwine stain (6-7). The possibility of Sturge Weber Disease must be thought in a child with facial nevi and history of seizures.

References

1. Haslam : RHA. Neurocutaneous Syndromes. In Behrman RE, Kliegman RM, Jenson HB (eds). Nelson Text book of Pediatrics. 17th edn. WB. Saunders Company, Philadelphia 2004 : 2015-19.
2. Berg Bo. Neurocutaneous Syndromes. In : Maria BL (ed) Current Management in Child Neurology. Hamilton BC Decker 1999. 278 - 80.
3. Gupte S. Phakomatoses. Gupte (S). The Short Text Book of Pediatrics. 10th edn. New Delhi : Jaypee Brothers 2004 pp 356.
4. Rochkind S. Hoftman HJ, Hendricks ED. Sturge Weber Syndrome. Natural history and prognosis. *J Epilepsy* 1990 ; 3 : 293-99.
5. Frieden IJ, Reese V, Cohen D. The association of posterior fossa brain malformations, hemangiomas arterial anomalies, coarctation of aorta and cardiac defects and eye abnormalities. *Arch Dermatol* 1996 ; 132 : 307.
6. Kalra V, Neurocutaneous Syndromes. In Ghai OP, Gupta P, Paul V (eds). Ghai Essential Pediatrics. 6th edn. New Delhi. Mehta Publishers 2004 pp 546.
7. Tan OT, Sherwood K, Gilchrist BA. Treatment of Children with portwine stains using the flashlamp pulsed tunable eye laser. *N Eng J Med* 1989 ; 320 : 416.