

Intracorporeal Lithotripsy for Ureteral Calculi Using Swiss Lithoclast : SKIMS Experience

Arif Hamid, M. Saleem Wani, B. S. Wazir

Abstract

At present the techniques available for performing intracorporeal lithotripsy include electrohydraulic, ultrasonic, laser, and ballistic lithotripsy. We present our experience with a unique technology for performing intracorporeal lithotripsy, namely the Swiss lithoclast, which is a form of ballistic lithotripsy. This simple and inexpensive device uses compressed air to activate a solid probe in a manner similar to that of a jackhammer. We report the use of this lithoclast in 92 patients involving a total of 95 ureteral calculi. The lithoclast successfully fragmented 81 of the 95 calculi, a success rate of 85.26%. There were no major complications directly related to the use of this device. The Swiss lithoclast seems to be a safe, effective and an inexpensive means of performing intracorporeal lithotripsy for ureteral calculi.

Key Words

Ureteral calculi, lithotripsy, Swiss lithoclast

Introduction

The advent and development of extracorporeal shock wave lithotripsy (ESWL) has revolutionized the treatment of renal and ureteral calculi. However, many patients with ureteral calculi are managed most effectively by direct vision intracorporeal lithotripsy. With advances in technology, decreasing morbidity, and attractive cost profile, ureteroscopic stone manipulation has attained a firm place in the treatment of ureteral calculi. Currently available modalities for performing intracorporeal lithotripsy include electrohydraulic, ultrasonic, laser, and ballistic lithotripsy. These modalities have generally proved to be safe and effective when used under direct vision. We report our experience with the use of Swiss lithoclast, a form of ballistic or pneumatic lithotripsy, for intracorporeal lithotripsy of ureteral calculi.

Material and Methods

The Swiss lithoclast was developed by the department of Medical Electronics and Urology at the University teaching hospital in Lausanne, Switzerland (1).

It was the first ballistic lithotrite. The device basically consists of a generator, a hand piece, and metal probes. The metal projectile in the hand piece of the lithoclast is propelled by measured bursts of compressed air against the head of a metal probe at the frequency of 12 cycles per second, thus activating the probe. The probe tip is placed against the stone to achieve stone fragmentation (Fig. 1). The lithoclast is activated by a foot pedal. A suction device connected to the lithoclast probe allows evacuation of stone particles (2).

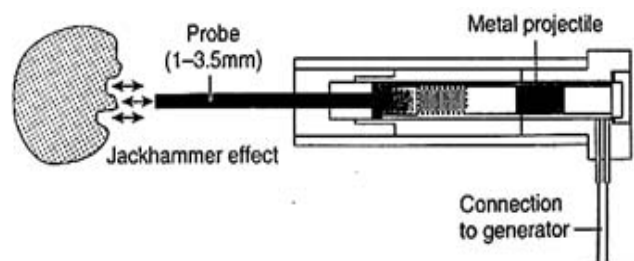


Fig. 1 Lithoclast hand piece mechanism

**From The Department of Urology, Sher-i-Kashmir Institute of Medical Sciences, Srinagar, J&K-190011, India.
Correspondence to:** Dr. M. Saleem Wani, Asstt. Prof., Deptt. of Urology, SKIMS, Soura, Srinagar, J&K, India.

Between May 2003 and May 2004, 92 patients, with a total of 95 ureteral calculi were treated with the Swiss lithoclast at our center. There were 58 males and 34 females. The right sided, left sided, and bilateral calculi were 57, 32, and 3 respectively. Sixty-eight calculi were distal ureteral, 19 mid-ureteral, and 8 proximal ureteral in location. 7 calculi were less than 6 mm, 66 between 6 and 10mm, and 22 greater than 10 mm in size. A radiological work up was done in all patients, consisting mainly of an ultrasound abdomen and intravenous urography. Retrograde pyelography and non-contrast CT of the abdomen was used in certain patients where other investigations were inconclusive. Radionuclide imaging was used in some patients, mainly to quantify the function of the involved renal unit. All patients received single preoperative broad spectrum parenteral antibiotic at the time of anesthesia induction. A morning x-ray KUB was obtained in all patients. Most of the patients were treated under general anesthesia. Equipment used mainly consisted of the Swiss lithoclast and 8/9.8 F rigid ureteroscope. Introduction of ureteroscope into the ureter was aided by a guidewire and 4F ureteric catheter. Once the stone was visualized, the metal probe was introduced via the ureteroscope and stone fragmented. After completion of the procedure any retrieved stone fragments/particles were analysed to know the chemical composition of the stone. Auxiliary procedures performed included ureteral dilatation in 5 patients, placement of a JJ stent in 41 patients, and PCN in one patient. Second parenteral antibiotic dose was administered in the evening. Oral antibiotics and analgesics were prescribed for 3-5 days. A check X-ray KUB was performed on the first post-operative day and another on the 7th postoperative day. Majority of the patients were discharged on the first postoperative day. JJ stent was removed in 2-3 weeks time. Final results were assessed at 3 weeks postoperatively.

Results

Successful fragmentation and clearance was achieved in 81 stones and incomplete fragmentation/clearance in six. Three stones had retrograde migration

into the proximally dilated upper urinary tract, while 5 stones could not be reached or visualized (Table 1). Of the 14 failed cases, second setting with ureteroscopic fragment retrieval was used in 2, placement of a JJ stent helped in 5, while open surgery was required in 7 cases.

Complications included mild hematuria in 54

Table 1. Results in 95 ureteral calculi treated

Result	No.	Percentage
Complete fragmentation and clearance	81	85.26%
Incomplete fragmentation / clearance	6	6.31%
Stone migration	3	3.15%
Stone not reached	5	5.26%

patients, moderate hematuria in 5, pain (colic) in 8, and fever in 7 patients. Twelve patients had documented UTI after the procedure. Two patients developed false passage in the intramural ureter (Table 2). All these minor complications were managed conservatively. There were no major complications like perforation, avulsion, or urosepsis. Patients are under followup and long-term complications are being assessed. An overall success rate of 85.26% was seen in the present series.

Discussion

Table 2. Complications

Complication	No.	Percentage	
Hematuria	Mild	54	56.84%
	Moderate	5	5.26%
Pain (colic)		8	8.42%
Fever		7	7.36%
UTI		12	12.63%
False passage		2	2.10%

The management of ureteral calculi represents one of the complex problems in urological practice. Several factors are to be considered simultaneously, including the size, nature, and location of the stone, the symptoms and morbidity caused by the stone, the medical condition of the patient, and other socio-economical factors. Available treatment modalities then need to be evaluated for their efficacy and morbidity. These considerations make the management of ureteral calculi uniquely challenging. Fortunately, during the past two decades, a variety of new therapeutic modalities have been developed with the aim of providing effective

treatment and at the same time minimizing the untoward effects of therapy.

Since its introduction in 1980, extracorporeal shock wave lithotripsy (ESWL) has quickly evolved as the treatment of choice for the majority of renal and ureteral calculi (3). However, some patients remain who are better managed by endourological techniques. In this regard percutaneous and transurethral ureteroscopic extractions of calculi have become well-established endourological techniques (4).

Several devices are available for achieving intracorporeal stone destruction. Electrohydraulic lithotripsy (EHL) for the treatment of urinary tract calculi has been available since the late 1950 (5). The principle for EHL is based on the effect of an electric discharge in a liquid medium creating a cavitation bubble that generates a hydraulic shock wave that impacts on the stone. Raney (6) in 1979 reported a success rate of 80% in dogs but a 40% rate of ureteral extravasation. As smaller ureteral probes were developed, there was an improved success rate and safer application of the technique, which increased general acceptance of this technology. Despite the development of very fine probes that have indeed decreased the perforation rate, ureteral injury is still a concern during ureteroscopy with EHL. Laser lithotripsy is another form of treatment modality available. Currently, the Holmium: YAG laser is the most effective and versatile intracorporeal lithotripter with a good margin of safety. The holmium laser lithotripsy occurs primarily through a photo-thermal mechanism that causes stone vaporization (7). The technique involves the placement of the laser fibre on the stone surface before activating the fibre and stone fragmentation occurs in a drilling fashion. The major drawback is the expense of equipment acquisition as well as equipment maintenance and the disposable elements required, limiting its use only in larger centres.

The ultrasonic lithotripter is based on the principle of converting electric energy into a sonic wave. The ultrasound wave is transmitted along a hollow or solid rigid probe, thereby inducing strong vibrations at the tip of the probe, which when applied to a calculus results in

fragmentation. Mulvaney (8) in 1953 first reported the use of ultrasound vibrations to break renal calculi. The major advantage is the efficient combination of stone fragmentation and simultaneous fragment removal. However, ultrasonic lithotripsy is used infrequently for ureteroscopy at most centres, largely because of the availability of other forms of lithotripsy developed for the ureteroscope.

The Swiss lithoclast, introduced in the early 1990s was the first ballistic lithotrite. Ballistic energy is a form of energy generated by the movement of a projectile. Several stimuli can induce the initial movement of the projectile. Once the projectile is in contact with another object, the ballistic energy is transferred to the object. Flexible objects preserve the momentum of the wave, but inflexible object, such as a stone, fragment on impact, a “jackhammer” effect. Denstedt and colleagues used this device clinically in the ureter, where they were able to treat successfully 15 of the 17 stones (9). Wadhwa and colleagues evaluated the use of Swiss lithoclast in the management of urinary calculi in 60 patients with a total of 61 calculi. Forty patients had a ureteric calculus. They reported that all those with a ureteric calculus were stone-free at 6 weeks (10). Terai *et al* (11) reported their experience with the Swiss lithoclast in the endoscopic management of urinary calculi. They reported an overall success rate of 94% independent of stone composition and concluded that Swiss lithoclast was a safe and effective means of intracorporeal lithotripsy although the device had a risk of retrograde stone migration in patients with upper ureteral stones. In another report, Murthy & associates compared a group of 25 patients treated using a rigid ureteroscope and 3 F ultrasonic solid probe with a group of 122 patients treated using the lithoclast. The overall success rate was significantly higher for the lithoclast group than for the ultrasonic group, 97.3% versus 84%, respectively (12). In our series the overall success rate was 85.26%. The failures were mostly related to either retrograde migration of the stone into the dilated proximal urinary tract or inability to reach the stone site.

The actual rate of incomplete fragmentation / clearance was 6.31% only.

The Swiss lithoclast is a unique device that adds to the currently available armamentarium for performing intracorporeal lithotripsy. Advantages of this device include its simplicity, reliability, and ease of use for the urologist and other nursing personnel. Another advantage is that no disposable elements are required, which adds to the cost effective aspect of this device. There is no heat generated during activation, making it a safer treatment modality. However, before activating the probe, the stone must be clearly visible and the probe should be directly applied to the stone without intervening ureteral mucosa.

Conclusion

In conclusion, we found the Swiss lithoclast to be safe and effective in fragmenting ureteral calculi. The simplicity, reliability, and ease of use make it a versatile and economical method to achieve successful intracorporeal lithotripsy.

References

1. Languetin JM, Jichlinski P, Favre R *et al.* The Swiss Lithoclast. *J Urol* 1990; part 2, 143: 179A, abstract V-32.
2. Delvecchio FC, Kuo RL, Preminger GM. Clinical efficacy of combined lithoclast and lithovac stone removal during ureteroscopy. *J Urol* 2000a; 164: 40-42.
3. Chaussy CG, Schmidt E, Jocham D *et al.* First clinical experience with extracorporeally induced destruction of kidney stones by shock waves. *J Urol* 1982; 127: 417-20.
4. Huffman JL, Bagley DH, Shoenberg HW *et al.* Transurethral removal of large ureteral and renal pelvic calculi using ureteroscopic ultrasonic lithotripsy. *J Urol* 1983; 130: 31-34.
5. Rouvalis P. Electronic lithotripsy for vesical calculus with "Urat-1". An experience of 100 cases and an experimental application of the method of stones in the upper urinary tract. *Br J Urol* 1970; 42: 486-91.
6. Raney AM. Electrohydraulic ureterolithotripsy: Preliminary report. *Urology* 1978; 12: 284-85.
7. Wollin TA, Denstedt JD. The holmium laser in urology. *J Clin Laser Med Surg* 1998; 16: 13-20.
8. Mulvaney WP. Attempted disintegration of calculi by ultrasound vibrations. *J Urol* 1953; 70: 704-07.
9. Denstedt JD, Eberwein PM, Singh RR. The Swiss lithoclast: a new device for intracorporeal lithotripsy. *J Urol* 1992; 148: 1088-90.
10. Wadhwa SN, Hemal AK, Sharma RK. Intracorporeal lithotripsy with the Swiss lithoclast. *Br J Urol* 1994; 74: 699-702.
11. Terai A, Takeuchi H, Terachi T *et al.* Intracorporeal lithotripsy with the Swiss lithoclast. *Int J Urol* 1996; 3: 184-196.
12. Murthy PV, Rao HS, Meherwade S *et al.* Ureteroscopic lithotripsy using mini-endoscope and Swiss lithoclast: Experience in 147 cases. *J Endourol* 1997; 11: 327-30.

8th NATIONAL CONFERENCE
INDIAN SOCIETY FOR PRENATAL DIAGNOSIS & THERAPY
February 17-19, 2006, India Habitat Centre, New Delhi
Organized by : DELHI SOCIETY FOR PRENATAL DIAGNOSIS & THERAPY
CALL FOR PAPER / POSTER, REGISTRATION

CONGRESS SECRETARIAT :

Room No. 3073, 3rd Floor, Teaching Block, AIIMS, Deptt. of O&G, Ansari Nagar, New Delhi - 110029.

Ph. 26593566, 9871439533, 26594585.

e-mail : dpk_deka@yahoo.com; madhulikakabra@hotmail.com

For more information, contact Secretariat/visit website

www.aiims.edu/ispatcon2006; www.aiims.ac.in/ispatcon2006