

Hyper-reactio Luteinalis associated with Hypothyroidism

N. Mittal, S. Mittal, V. Dhadwal, P.V.L.S. Swarupa

Abstract

Hyper-reactio luteinalis is a non-neoplastic tumor-like ovarian lesion associated with pregnancy. Most patients are asymptomatic, with the ovarian enlargement being incidentally discovered at the time of cesarean section. We report a case of hyper-reactio luteinalis in a pregnant woman with profound hypothyroidism.

Key words

Hyper-reactio luteinalis, Ovarian enlargement, Pregnancy, Theca lutein cysts

Introduction

Hyper-reactio luteinalis (HL) is a rare benign condition associated with marked cystic enlargement of ovaries due to multiple theca lutein cysts (1). HL is generally diagnosed incidentally at the time of cesarean section with spontaneous regression during postpartum. Occasionally patient may present with abdominal distention or pain from either ovarian torsion or hemorrhage. HL is rare in normal pregnancy and is usually associated with pregnancies characterised by excessive human chorionic gonadotropin (hCG) production such as gestational trophoblastic disease, hydrops fetalis and multiple pregnancies (2). It has also been reported that a pre-existing endocrinopathy such as polycystic ovarian disease may predispose to the development of this lesion in some cases by an exaggerated reaction of the ovarian stroma to hCG. We report a case of hyper-reactio luteinalis associated with profound maternal hypothyroidism in a spontaneously conceived singleton pregnancy.

Case Report

A 26 year old gravida 3, para 2 with previous history of two still births presented to the emergency services of AIIMS hospital with amenorrhoea of 4 months and abdominal distention of one month duration associated with intermittent abdominal pain and dyspnoea on exertion. On examination her pulse was 76/min and blood pressure was 140/80 and chest was clear on auscultation. Her abdomen was distended and tense with an irregular mass of 20x20cm size arising out of pelvis associated with ascitis.

A trans-abdominal ultrasound showed a single viable intrauterine pregnancy of 14 weeks gestational age. Both ovaries were enlarged, the right ovary measured 152x98 mm and left one 136x96 mm in the largest cross section, both showed multiple cysts of varying diameter between 26 and 48 mm. Some of these cysts showed an echogenic portion in the center, the placenta was normal and there was moderate amount of ascitis. Trans-abdominal colour doppler sonography revealed peripheral and interseptal

From the Deptt. of Obstetrics & Gynaecology, All India Institute of Medical Sciences, New Delhi.

Correspondence to : Dr. Vimala N, Deptt. of Obstetrics & Gynaecology, All India Institute of Medical Sciences, New Delhi.

vascularisation with moderately high resistance to blood flow. The possibility of either benign theca lutein cysts or an epithelial ovarian tumor was suggested.

The patient was admitted for further evaluation and treatment. The routine laboratory investigations including CA-125 (10.48 IU/ml), fetoprotein (28µg/l) and -HCG (>100,000 IU) were within normal limits, her chest x-ray was normal. A cytological analysis of ascitic fluid was negative for malignancy. The cysts continued to grow reaching maximum size at 18 weeks gestation, by which time the abdomen was grossly distended from costal margins to the symphysis pubis.

In view of uncertainty of diagnosis and increasing maternal distress the decision was made to undertake patient for laparotomy. Intraoperatively, uterus was enlarged to the size of 18 weeks gestation, both ovaries were enlarged with multiple cysts varying in size between 3-5cm diameter, with hemorrhage in some cysts. These cysts were resected. Although there was no recognisable ovarian tissue in proximity to the ovarian pedicle, layers of cortex were dissected off the cysts and the ovaries were reconstituted on both sides. Cut surface of the resected cysts were smooth walled, containing clear fluid with focal solid areas. Histopathologic examination revealed multiple theca lutein cysts lined by luteinised granulosa cell layer. Cysts were separated by thin bands of edematous stroma containing theca lutein clusters.

On postoperative day 3, the patient had rupture of membranes and subsequent spontaneous abortion of a male fetus weighing 320 gms with no gross congenital anomalies. The placenta and membranes were normal. The rest of postoperative period was uneventful.

After confirming the diagnosis of HL, baseline hormone profile was done. The levels of FSH, LH, and testosterone were within normal range but TSH was found to be markedly elevated (100mIU/ml). She was diagnosed to have primary hypothyroidism, started on L.thyroxine and was discharged on 12th postoperative day. On follow up visits at 4, 8 and 12 weeks period, the TSH levels showed a declining trend and she had her normal menstrual periods 6 weeks following surgery.




Fig. 1. Partially removed ovary with multiple cysts.

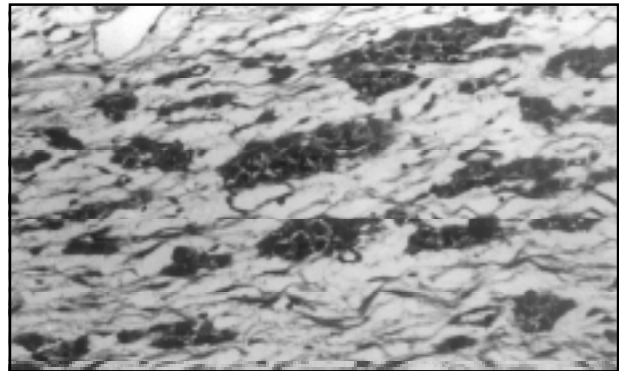


Fig. 2. Theca-lutein cells without signs of malignancy, degeneration or cell death.

Discussion

Hyper-reactio luteinalis is usually asymptomatic. It may be discovered during a routine pelvic ultrasound for pregnancy, during caesarean section or sometimes post partum. In symptomatic cases, patients may present with abdominal bloating or cyst complications, such as torsion and haemorrhage. In some cases it may be associated with fluid shift. Lambers et al described a case of hyperreactio luteinalis associated with normal singleton pregnancy where pregnancy termination was carried out for maternal respiratory decompensation secondary to pleural effusion and ascites (3). O'Loughlin et al reported a 16 weeks pregnant patient who presented with dyspnoea and abdominal discomfort secondary to massive ascites and pleural effusion and underwent exploratory

laparotomy with partial ovarian resection (4). In this case also laparotomy was performed because of increasing maternal distress due to rapid enlargement of ovaries and uncertainty of diagnosis.

The pathophysiological features of HL are still poorly understood, due to the frequent association with trophoblastic disease, it has been attributed to elevated human chorionic gonadotropins (hCG) (5). However our patient had not received exogenous ovarian stimulation and endogenous gonadotropin levels were within normal limits. The laboratory tests results in our patient are consistent with profound hypothyroidism.

The causal association between the hypothyroidism and development of hyper-reactio luteinalis is supported by data from animal research. Scommegna et al have reported that the development of ovarian follicular cysts in rats can be stimulated by drug induced hypothyroidism (6). It has been demonstrated in multiple species that perinatal exposure to thyroid stimulating hormone in vivo and in vitro causes a hormonal imprinting effect with a durable amplification of the response to subsequent follicle stimulating hormone receptor binding. However, these findings in humans are speculative and remains to be demonstrated, but is conceivable that an unrecognised profound hypothyroidism in our patient sensitized the ovarian follicle to a potentiated follicle stimulating hormone

response. An increase in capillary permeability to protein in patients with hypothyroidism has been demonstrated (7), which may account for the high concentration of proteins in effusion and could have contributed to an increased fluid accumulation in the ovarian follicles.

The exact mechanism by which HL was caused in our patient can only be speculated on the association of hypothyroidism and HL deserves further attention.

References

1. Clement PB. Tumor like lesions of the ovary associated with pregnancy. *Int J Gynecol Pathol* 1993; 12:108-15.
2. Girouart DP, Barclay DP, Colhns CG. Hyperreactioluteinalis. Review of literature and report of two cases. *Obstet Gynecol.* 1964; 23: 513-25.
3. Lambers DS, Rosenn B. Hyperreactio luteinalis complicating a normal singleton pregnancy. *Am J Perinatol* 1996; 8: 491-93.
4. O'Loughlin J and Brookes CM. Massive multiple theca lutein cysts complicating nonmolar pregnancy. *Aust NZ J Obstet Gynecol* 1987; 27: 166-68.
5. Schnorr JA, Miller H, Davis JR, Hatch K, Seeds J. Hyperreactioluteinalis associated with pregnancy: A case report and review of the literature. *Am J Obstet Gynecol* 1996; 13: 95-97.
6. Scommegna A, Castillo E, Borushek S, Gold JJ. Factors in polycystic ovary development: Role of the pituitary in rat. *Fertil Steril* 1965; 16: 571-73.
7. Ingbar SH. The thyroid gland. In: Wilson JD, Foster DW (eds). *Textbook of endocrinology*. WB Saunders Philadelphia, 1985; pp 682.

GUIDELINES FOR ARTICLES TO BE SUBMITTED UNDER EACH CATEGORY TO
"JK SCIENCE" JOURNAL OF MEDICAL EDUCATION & RESEARCH

Article Type	Summary: No. of Words	Key Words: No. of Words	Text: No. of Words	Sub-Headings	Tables: Max. No.	Figures: Max. No.	No. of References
ED	NR	NR	≤ 600-800	NR	NR	NR	≤ 10
RA	NR	NR	≤ 3000	Variable	2	2	30-35
OA	≤ 200	3-5	≤ 2000	Standard	4	2	20-25
SC	≤ 100	3-5	≤ 1200	Standard	2	1	10-15
CR	< 50	3-5	≤ 600-800	Standard	1	3	≤ 10
DR	NR	NR	≤ 1000	NR	1	1	≤ 10

ED = Editorial; RA = Review Article; OA = Original Article; SC = Short Research Communication; CR = Case Report; DR = Drug Review