

## Anterior Segment Changes Following Bee Sting to Cornea

Imtiyaz Ahmad Lone, Azra Rizvi, Sheikh Sajjad Ahmad, Reyaz Ahmad Untoo

### Abstract

We present a rare case of bee-sting to the cornea which leads to a variety of changes involving the anterior segment of the eye.

### Key Words

Bee-Sting, Cornea, Iridocyclitis, Cataract

### Introduction

Bee sting to the cornea is rare but among the more frequently encountered traumas caused by insects. Hypersensitivity to stinging insects with serious or fatal anaphylactic reactions is confined almost entirely to the Hymenoptera, the most troublesome of which are honeybees, paper wasps, hornets and yellow jackets (1).

Acutely, conjunctival hyperemia and chemosis usually occur, sometimes associated with severe pain, corneal edema and infiltrate with subsequent decreased vision. The variability of the acute response is thought to reflect differences in the quantity of the venom injected and whether the reaction to the venom is toxic or immunologic.

A 12 year old school boy with a history of bee sting to the cornea 1 month back and followed by decreased vision is hereby presented for its rarity.

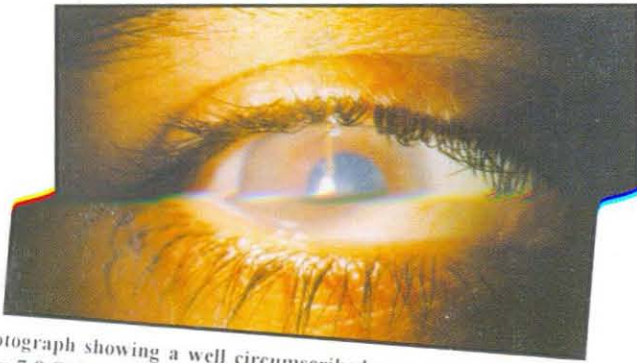
### Case Report

A 12 year old boy presented to the eye OPD with decreased vision in right eye since 1 month. He gives a history of honeybee sting on the right eye 1 month back. Immediately after the sting the patient developed redness and severe pain in the eye, which however subsided within a few days following the use of topical antibiotics and mydriatics.

Examination of the right eye revealed a dense oval corneal opacity extending from 7 to 9 O'clock with surrounding epithelial bedewing and stromal haze. The iris was markedly hypochromic and the pupil semi-dilated with no response to miotics. There was a star-shaped central lenticular opacity involving the anterior capsule and the anterior cortex. Visual acuity was 6/24 with no further improvement with glasses. The IOP was normal, although gonioscopy revealed pigmentation of the trabecular meshwork.

From the Department of Ophthalmology, SKIMS Medical College, Bemina, Srinagar (J&K) India.

Correspondence to : Dr. Imtiyaz Ahmad Lone, Senior Resident, Deptt. of Ophthalmology, SKIMS Medical College, Bemina, Srinagar.



Photograph showing a well circumscribed corneal opacity extending from 7-9 O'Clock and markedly hypochromic iris and cataract.

### Discussion

The reaction to bee-sting is usually violent. There is typically a striate keratitis. Frequently, however, the epithelium desquamates, there is considerable stromal turbidity or even necrosis, sometimes associated with an exudative iridocyclitis and hypopyon (2) and occasionally with an anterior polar cataract. The cataract is marked by a local degeneration of the capsular epithelium with collection of fluid between the cells and the damaged fibres.

Stinging insects (including honey-bee) inject venom into the tissue. In venom, there is histamine, serotonin, acetylcholine, kinin, hemolysin, neuro-toxins,

hyaluronidase, mellitin, apamine and formic acid. The major allergen in honey-bee venom may be phospholipase-A or a combination of high molecular weight material and hyaluronidase (1). The mydriasis ~~is~~ <sup>is</sup> ~~due to~~ <sup>due to</sup> ~~the~~ <sup>the</sup> ~~paralytic~~ <sup>paralytic</sup> effect of the neuro-toxins (3).

Since the non-allergic inflammatory response that occurs after honey-bee sting is primarily a toxic inflammatory response to mellitin or formic acid, it is clear that insect stings cause both immunologic and non-immunologic responses. The allergens in the venom cause a type-I IgE mediated hypersensitivity response. There may be binding of complement as well as some of the components of the venom. Activation of the complement cascade results in inflammation of the affected tissue.

### References

1. Donshik PC, Ehlers WH. Occular allergy. In: Smolin G, Thoft RA (eds). *The Cornea* 3rd edition Lippincott Williams & Wilkins, Philadelphia 1994, pp 35-60.
2. Nirankari and Sangha. *Orient Arch Ophthalmol* 1967; 5 : 125.
3. Landers PH. Mud dauber wasp venom in anterior chamber. *Am J Ophthalmol* 1967 ; 64 : 1168 .