



## Role of Combined Approach with Radiotherapy and Metallic Stent in Palliation of Advanced Cases of Carcinoma Esophagus - A Pilot Study

Chander Mohan Sehgal, Rakesh Raman Sharma, Rakesh Kapoor, D. R. Goel, F. D. Patel,  
S. C. Sharma, Usha Dutta\*, K. Raja\*, Kartar Singh\*

### Abstract

Carcinoma esophagus presents with dysphagia and in 60% of patients, the aim of treatment is palliation. This study was done to evaluate the feasibility and role of planned combined approach using radiotherapy with metallic stent in palliation of malignant dysphagia. Ten patients with histologically proven, locoregionally advanced esophageal carcinoma were selected. All patients underwent external radiotherapy followed by brachytherapy. The self-expanding metallic stent was placed under combined endoscopic and fluoroscopic guidance. A predetermined questionnaire to assess dysphagia, pain, reflux symptoms and quality of life was administered before the procedure, and thereafter at monthly intervals until death or last follow-up. 10/10 patients had grade III dysphagia at presentation. 4/10 patients underwent stent placement prior to any radiotherapy (group A), 4/10 patients had stent placement after external radiotherapy (group B) and 2/10 had stent after completion of brachytherapy (group C). There was no difficulty in placing the stent despite the post-radiotherapy ulcerations and stricture in all the patients in group B and C. 8/8 patients in groups A and B had no difficulty in placing esophageal bougie for brachytherapy. The mean follow-up after stent placement was 9 months (4-24 months). There was complete disappearance of dysphagia in 4/4 patients in group A, 2/4 patients in group B and 0/2 patients in group C. The rest of patients had significant improvement in dysphagia score by atleast two grades. For dysphagia grade, the mean progression free interval was recorded as 5 months for group A, 3 months for group B and 2 months for group C. Combining radiotherapy and metallic stent is a safe, simple and effective means to palliate malignant dysphagia. This raises an issue whether all patients with advanced carcinoma esophagus should preferably be pre planned for stent placement followed by radiotherapy for best results.

### Key Words

Carcinoma esophagus, Dysphagia, Metallic stent

### Introduction

Despite advances in the treatment of esophageal cancer, 50-60% of patients are incurable at presentation (1,2). The prognosis of this malignancy is dismal, with a 5-year survival rate of only 5% to 10% (3). Progressive dysphagia is the most common symptom of esophageal malignancy, therefore, the principle goal of palliation is

to maintain a patent esophageal lumen. In our set up, more than 80% patients with esophageal malignancy are loco-regionally advanced at diagnosis. In these patients, dysphagia is the principal problem that limits the quality of life. Only realistic goal is palliation of dysphagia. Improvement in dysphagia improves quality of life. Laser

From the Department of Radiotherapy and \*Gastroenterology, PGIMER, Chandigarh - 160012, India

Correspondence to : Dr. Rakesh Kapoor, Assistant Professor, Department of Radiotherapy PGIMER, Chandigarh - 160012, India

photoablation, external radiotherapy, intraluminal radiotherapy, chemotherapy, photodynamic therapy, endoscopic dilation and esophageal prostheses have all been used for palliation (4-10). Until last decade, the main stay of treatment in these advanced patients has been external radiotherapy in palliative doses. Over the last decade, intraluminal high dose rate brachytherapy has evolved as an important modality to relieve malignant dysphagia. A combination of both external beam radiotherapy and brachytherapy is an effective form of palliative therapy (11,12). Esophageal prostheses have been considered by many as the "ultimate form of palliative treatment" as most patients undergo stent placement after they have received radiotherapy (13). Experience of combined approach using radiotherapy with a stent for dysphagia relief is very limited. There are fears about combining radiotherapy and metallic stent in these patients because of potential complications. As would be desirable, the best palliation from dysphagia and other symptoms may perhaps be achieved if it is feasible to combine both radiotherapy and metallic stent.

### Objectives

1. To evaluate the feasibility and role of planned combined approach using radiotherapy with metallic stent in the palliation of malignant dysphagia.
2. To compare the benefit and complications with stent prior to radiotherapy versus stent after radiotherapy.
3. To study the change in quality of life before and after such combined treatment.

### Patients & Methods

From June 1999 to January 2001, 10 patients of advanced carcinoma esophagus patients were planned to undergo both radiotherapy and stent placement. Six patients were men and 4 were women, the age range was 30-77 years (median, 51 years). All patients had squamous cell carcinoma. Nine patients had malignant obstruction of the mid esophagus and one in the distal portion. Tumor length varied from 4-9 cm (Table 1).

**Table 1: Patients Characteristics**

Characteristics	n=10
Gender	
Male	6
Female	4
Age (years)	30-77 (Median age - 51 years)
Site of Tumor	
Middle 1/3rd esophagus	8
Lower 1/3rd esophagus	2
Mean length of tumor	6.2 cm (range 4-9 cm)
Histology (biopsy proven)	
Squamous cell carcinoma	10

Patients were divided into three groups A, B and C depending on the time of stent placement. Four patients were planned to undergo stent placement from beginning followed by radiotherapy (group A), four patients underwent stent placement after completing external radiotherapy because of stenosis (group B) whereas two patients underwent stent placement after they had received both external radiotherapy and brachytherapy but had dysphagia recurrence (Group C) (Table 2).

**Table 2 : Study Design**

Groups	Time of stent placement	N=10
<i>Group A</i>	Before starting any radiotherapy	4/10 (1 fistula)
<i>Group B</i>	After completing external radiotherapy but before brachytherapy	4/10
<i>Group C</i>	After completing EBRT +brachytherapy	2/10

### Technique of Treatment

#### Radiotherapy

External beam radiotherapy was delivered on megavoltage teletherapy (Cobalt 60 or 6 MV linear accelerator) to a dose of 30-35 Gy/10-15 #/2-3 weeks.

Brachytherapy is delivered with an endoscopically placed intraluminal esophageal bougie to a dose of 6 Gy x 2 fractions, at one week interval on high dose

rate (HDR, Iridium-192) microselectron. All patients underwent this procedure on outpatient basis.

**Endoscopic stent placement**

Stent material: Self expandable metallic stent was used (Ultraflex, Microvasive, Nitinol material, Boston Scientific USA, 18 mm expanded diameter, 10 cm or 15 cm length) (Fig 1). Endoscopy was initially performed for assessment of the malignant lesion and/or stenosis. Dilatation, if necessary, was carried out using a wire-guided dilator and the endoscope passed beyond the lesion. This was followed by fluoroscopic and endoscopic stent placement using a stent delivery device under midazolam sedation. Visual confirmation was obtained that the proximal end of the stent is well above the proximal end of the stenosis. Covered stent was used for one patient with fistula (group A) whereas all the other patients received uncovered stent.

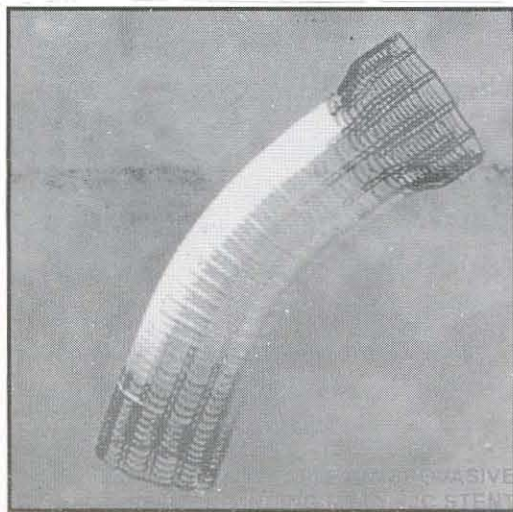


Fig. 1 : Ultraflex Microvasive Self Expanding Metallic Stent

**Assessment and follow up**

A predetermined quality of life score assessment questionnaire was administered before the procedure and thereafter at monthly intervals until death or last follow-up. This questionnaire included five questions (score - 1 through 5): 1. dysphagia grade, 2. severity of

pain, 3. enthusiasm in doing daily activities, 4. satisfaction with sleep, and 5. Karnofsky Performance Scale (0.5 score for KPS of 10). All complications were recorded. Monthly chest X-ray was done to check stent migration and barium swallow/ endoscopy was performed in case of dysphagia recurrence.

**Statistical analysis**

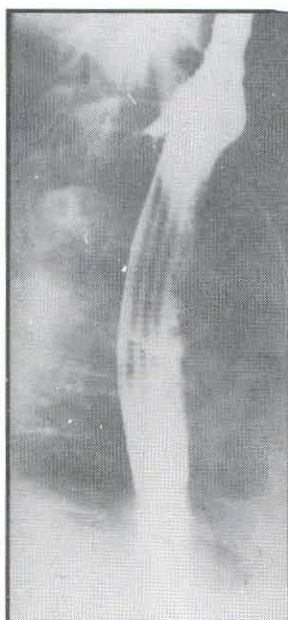
The results were recorded using chi square test and univariate analysis.

**Results**

In Groups B and C, there was no difficulty in placing the stent despite the post-radiotherapy ulcerations (6/6) and stricture (3/6). At the same time, 8 patients in Groups A and B had no difficulty in placing esophageal bougie for brachytherapy. The overall success in stent placement and brachytherapy was 100%. One patient with esophageal - airway fistula was effectively sealed by a covered stent (Fig. 2 & 3).

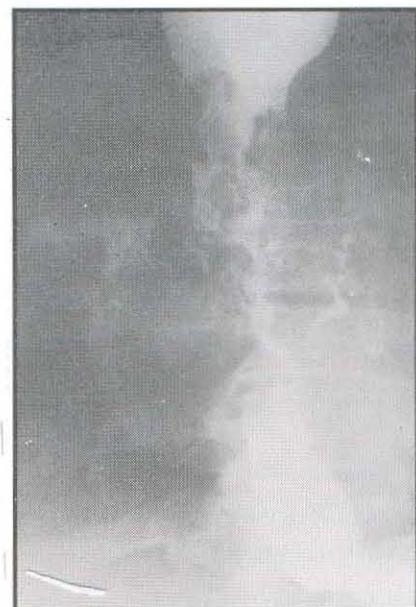

Fig. 2 : Carcinoma esophagus with esophageal-airway fistula



**Fig. 3 : Fistula effectively sealed by a covered stent**

Pre-stent placement dilatation was required in 3/10 patients. There was no immediate procedural complication. 8/10 patients underwent stent placement as outpatient procedure and 2 patients required indoor admission. The mean procedure time for stent placement was 20 minutes. No patient required admission for brachytherapy on HDR micro selectron.

### Complications after Stent Placement

#### Early complications (within 48 hrs)

Gastroesophageal reflux was noticed in 7/10 patients and was easily controlled. 6/10 patients complained of retrosternal pain which was severe in one patient in Group C. No life threatening complication was seen (Table 3).

#### Late complications (after 48 hrs)

One patient had hematemesis (Group C) 4 weeks after stent placement. Tumour in growth was seen in 3 patients and persistent gastroesophageal reflux was seen in 3 patients (1 in Group B and 2/2 in Group C) (Table 3).

**Table3 : Complications after Stent Placement**

Complications	Group A (n=4)	Group B (n=4)	Group C (n=2)
<b>Early (within 48 hours)</b>			
Gastroesophageal reflux	2	3	2
Retrosternal pain	2	2	2
<b>Late (after 48 hours)</b>			
Hematemesis	0	0	1
Migration	0	0	0
Chest pain	0	0	1
Tumour in growth (dysphagia)	0	1	2
Stricture	0	0	1
Gastroesophageal reflux (persistent)	0	1	2
<b>Total events</b>	<b>4</b>	<b>7</b>	<b>11</b>

Overall the rate of early and late complications was slightly higher for group C patients compared to group A and B ( $p > 0.05$ ).

Most of the complications were effectively controlled with medications. The mean follow-up after stent placement was 9 months (range 4-24 months).

There was complete relief of dysphagia in 3/4 patients in Group A, 2/4 patients in Group B and 0/2 patients in Group C. One patient in Group A who had fistula at diagnosis had relief in dysphagia from grade IV to grade I. Rest of the patients had significant improvement in dysphagia score by at least 1 grade. Dysphagia grade decreased from a mean of 3.20 to 0.80 and was sustained unless a specific complication arose. For dysphagia grade, the mean progression free interval was recorded as 5 months for Group A, 3 months for Group B and 2 months for Group C.

There was a mean weight gain of 6 kgs in 5 patients of Group A and B. Patients survived a mean of 5.5 months after completion of treatment and improvement in quality of life score was seen in total 7/10 patients (3/4 patients in Group A, 3/4 patients in Group B and 1/4 in Group C). But on comparison of pre-stent versus post-stent score, the patients in Group A did the best (Figure 2).

Fig. 1 : Symptoms at Presentation

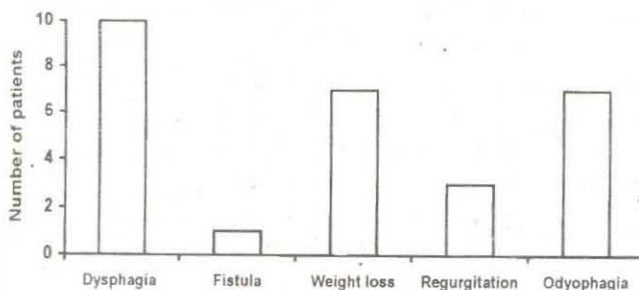
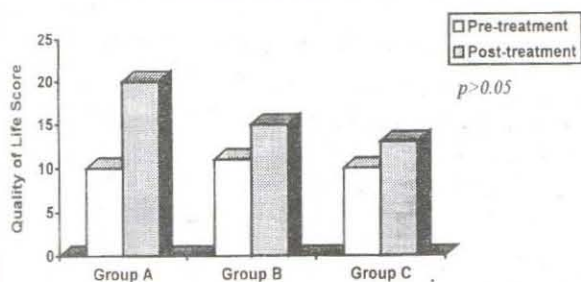


Fig. 2 : Change in Quality of Life Score



## Discussion

The treatment of esophageal malignancy is mainly palliative. The ideal method of palliative treatment would be a single procedure that is technically simple, well tolerated, does not require general anesthesia and lead to permanent symptomatic relief from dysphagia. Such treatment would improve the quality of life for these patients. There is general consensus that surgical palliation is not ideal in terms of effectiveness in relation to the patients quality of life (14). Other methods such as laser vaporisation or intubation all have specific shortcomings. Repeated sessions are necessary for dilatation and laser treatment (15).

Squamous cell carcinoma of esophagus is moderately sensitive to radiotherapy. The principle advantage with radiotherapy both external as well as internal (after loading) is that they produce rapid decompression of the tumour which leads to relief of esophageal obstruction and thus dysphagia relief. Intraluminal brachytherapy using high dose rate iridium 192 source has proven its efficacy in palliation of dysphagia which is attributed to very high dose delivered in a very short time (11,12).

Recently, esophageal prostheses have undergone modifications and self-expandable metallic stents (SEMS) are common in use. The principal advantage of SEMS is that they require a much smaller luminal diameter usually 5-10mm (30-35 Fr.) instead of the 17-22mm (50-66 Fr.) needed with a plastic tube for passage through the tumour stenosis, since they are introduced in a retracted form. After release, the expansile force further dilates the tumours upto an internal diameter of 18-20mm (16-18). SEMS have high elasticity, seem to have advantages in handling, relieving dysphagia and possibly no significant interactions with radiation (19).

Literature on the combined treatment using radiotherapy as well as stent is scanty although SEMS has been frequently used by gastroenterologists over last decade. Kinsman *et. al.* analysed the complications in 59 patients who had undergone stent placement (SEMS). Twenty-three late complications occurred in 22 patients (37.5%). Life threatening complications occurred in 9 patients (15%), including gastrointestinal bleeding (7), perforation (1), and tracheoesophageal fistula (1) and contributed to all five deaths. Eight of 22 patients with prior radiation and/or chemotherapy (36.4%) had life-threatening complications compared to 1 in 37 (2.5%) without prior therapy ( $p=0.001$ ). Stent-related mortality occurred in 5 of 22 (23%) patients with prior therapy compared to none of the 37 without prior therapy ( $p=0.005$ ) (20). Our data from present study shows that there is risk of both early and late complications which are minor and can be effectively treated with conservative management. Moreover, the overall risk as well as late complications are higher if stent is placed in patients who have already received radiotherapy (Table 3).

The issue of improving quality of life in patients with carcinoma esophagus is vital but poorly addressed. Our study shows that if stent can be placed at presentation followed by radiotherapy only then not only the incidence of complications is lower but the dysphagia relief



achieved is better compared to stent placement for dysphagia recurrence after radiotherapy (Fig.2). When compared with historical controls, the benefit in dysphagia and quality of life is better with radiotherapy and stent combined than that achieved with either radiotherapy alone or stent alone. This raises an issue whether all patients with advanced carcinoma esophagus should preferably be pre-planned for stent placement followed by radiotherapy for best results.

### Conclusion

Metallic stent in combination with radiotherapy is effective and safe for palliation of malignant dysphagia. The fear of reactions in patients treated with stent and radiotherapy is perhaps ill founded. In our set up, cost of stent may be inhibiting but the value of this combination in terms of dysphagia - relief and improvement in quality of life is appreciable. All patients with advanced carcinoma esophagus may be treated with initial stent placement at presentation followed by radiotherapy for best palliation.

### References

1. De Meester TR, Barlow AP. Surgery and current management for cancer of the esophagus and cardia; Part II. *Current Prob Surg* 1983 ; 25 : 540-65.
2. Boyce HW Jr. Palliation of advanced esophageal cancer. *Semin Oncol* 1984 ; 11 : 186-95.
3. Lambert R: Palliation of carcinoma of the esophagus: is that a hope for cure? *Am J Gastrol* 1994 ; 89 : 27-40.
4. Heier SK, Rottman K, Rosenthal WS. Photodynamic therapy for obstructing esophageal tumors: efficacy, safety, light dosimetry and results of an on-going randomized trial (abstract). *Gastrointest Endosc* 1991 ; 37 : A187.
5. Sander R, Hagenmuller F, Sander C, Riess G, Classen M. Laser Vs Laser plus after loading with iridium 192 in the palliative treatment of malignant stenosis of the esophagus: a prospective, randomized and controlled study. *Gastrointest Endosc* 1991 ; 37 : 433-9.
6. Fleischer D, Sirak M. Endoscopic Nd: YAG Laser therapy as palliation for esophagogastric carcinoma. *Gastrol* 1985 ; 89 : 827-31.
7. Loizou LA, Grigg D, Atkinson M, Robertson C, Bown SG. A prospective comparison of laser therapy and intubation in endoscopic palliation for malignant dysphagia. *Gastrol* 1991 ; 100 : 1303-10.
8. Right RA, O'Conner KW. A pilot study of endoscopic injection chemo/sclerotherapy of esophageal cancer. *Gastrointest Endosc* 1990 ; 36 : 47-8.
9. Mc Intire AS, Morris DL, Sloan RL *et. al.* Palliative therapy of malignant esophageal stricture with the bipolar tumor probe and prosthetic tube. *Gasrointest Endosc* 1989 ; 35 : 531-5.
10. Fleischer DE, Dull-Henry K. A new coated self-expanding metal stent for malignant esophageal strictures. *Gastrointest Endoc* 1992 ; 38 : 494-6.
11. Jager JJ, Pannebakker M, Rijken J, de Vos J, Vismans FJ. Palliation in esophageal cancer with a single session of intraluminal irradiation. *Radiother Oncol* 1992 ; 25 : 134.
12. Hareyama M, Nishio M, Kagani Y, Narimatu N, Saito A, Sakurai T. Intracavitary brachytherapy combined with external-beam irradiation for squamous cell carcinoma of the thoracic esophagus. *Int J Radiat Oncol Biol Phys* 1992 ; 24 : 235.
13. Axelrad AM, Flesicher DE. Esophageal tumors. In: Sleissenger MH, Fordtran JS, (editors). *Gasrointestinal and liver disease: pathophysiology/diagnosis/management*. Philadelphia: WB Saunders Company, 1998.
14. Grund KE *et. al.* *Endoscopy* 1995 ; 27 : 486-94.
15. Renwick P, Whitton V, Moglissi K. Confined endoscopic laser therapy and brachytherapy for palliation of esophageal carcinoma: a pilot study. *Gut* 1992 ; 33 : 435-438.
16. Fuchs KH, Freys SM, Schaube H *et. al.* Randomized comparison of endoscopic palliation of malignant esophageal stenoses. *Surg Endosc* 1991 ; 5 : 63-67.
17. Barr H, Krasner N, Raouf A *et. al.* Prospective randomized trial of laser therapy only and laser therapy followed by endoscopic intubation for the palliation of malignant dysphagia. *Gut* 1990 ; 31 : 252-258.
18. Cusumano A, Ruol A, Segalin A *et. al.* Push-through intubation: effective palliation in 409 patients with cancer of the esophagus and cardia. *Ann Thorac Surg* 1992 ; 53 : 1010-1014.
19. Kollath J, Liermann D, (eds.). *Stents II (conscientia diagnostica)*. Papers presented at the first international stent symposium, Frankfurt 1991: Schmelztor, Constance, Germany, 1992.
20. Kinsman KJ, DeGregorio BT, Katon RM *et. al.* Prior radiation and chemotherapy increase the risk of life-threatening complications after insertion of metallic stents for esophagogastric malignancy. *Gasrointestinal Endoscopy* 1996 ; 43(3) : 196-203.