

# A Rare Giant Pleomorphic Adenoma of Cheek

Shafkat, Mohd Lateef, Rouf Ahmad

## Abstract

We report here a rare case of pleomorphic adenoma in right cheek in a 80 year old male who presented to us with a unilateral, asymptomatic mass in right cheek.

## Key words

Major salivary glands, Minor salivary glands, Tumors, Pleomorphic adenoma

## Introduction

Salivary gland tumors comprise less than 3% of all tumors of head and neck.(1). Eighty percent are located in parotid,10% in the submandibular, the remainder being distributed between the sublingual and countless minor salivary glands (2-6). Minor salivary glands are found in the oral cavity, nose, paranasal sinuses, cheek, oropharynx, larynx and trachea. Although the giant tumors of major salivary glands are reported in the literature (7), but they are very rare in minor salivary glands especially minor salivary glands of cheek (7,8). We report a case of an 80-year-old male who presented with a unilateral, asymptomatic mass in the right cheek. Fine needle aspiration cytology (FNAC) of the mass revealed pleomorphic adenoma. Microscopic examination of the subsequent specimen confirmed the FNAC diagnosis.

## Case report

An 80 year old, non-smoker, male was admitted in the ENT Department of the Government Medical

College, Srinagar because of a painless, enlarging, swelling of right cheek with distortion of right oral commissure with 20 years of duration. Patient reported that the mass increased in size very slowly till it reached the present size. Local examination revealed 10x6 cm mobile, soft to firm, non-tender mass on the right side of face (Fig. 1). Skin over the swelling was freely mobile over the periphery but tethered in the centre. Underlying bone of the maxilla was not eroded. A downward displacement of right half of face with distortion of right oral commissure was noticed. Sensations over the swelling were intact. There was no ulceration or erosion. Facial nerve was intact. Buccal mucosa on the right side was ulcerated. Rest of the examination, local as well as systemic was normal. There was no involvement of lymph nodes. Investigations like haemogram, urine analysis and radiography was normal. Fine needle aspiration cytology revealed features of pleomorphic adenoma which were confirmed

From the Department of ENT, Government Medical College, Srinagar. (J&K) India.

Correspondence to : Dr. Shafkat, Senior Resident, Department of ENT, SMHS Hospital, Srinagar (J&K) India.

on histopathological examination (Fig. 2). Excision of the tumor was done under general anaesthesia. A pseudo-capsule was found covering the tumor. Tumor was removed enmass alongwith the tethered skin. Patient was discharged on 15th post-operative day. Patient reported after two years of surgery without any recurrence.

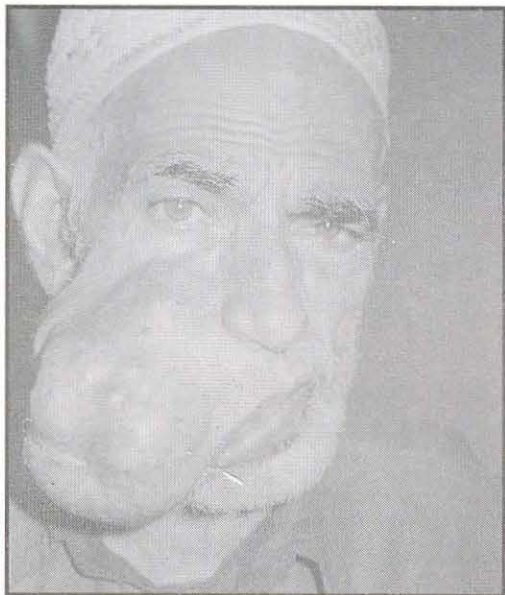


Fig. 1. Photograph showing swelling in right cheek

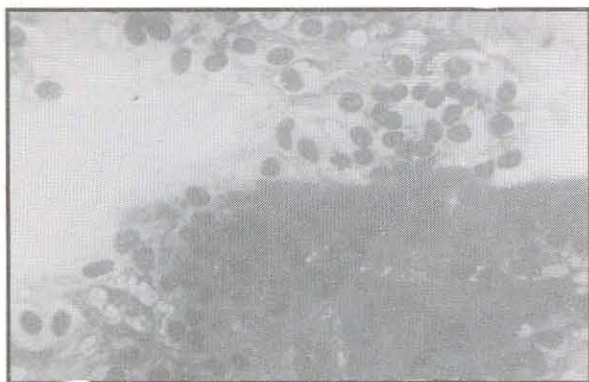


Fig. 2. Pleomorphic adenoma showing duct cells, myoepithelial cells and chondroid matrix. Giemsa x 400

## Discussion

Primary salivary gland tumors comprise less than 3% of all head and neck tumors (1). Minor salivary gland tumors alongwith the sub-lingual tumors constitute less than 10% of all salivary gland tumors (2,3,4,6). In minor salivary glands, malignant tumors outnumber the benign tumors (9-11).

There were no known predisposing factors. There was no malignant change even after a long standing history in comparison to malignant changes in 6% of the pleomorphic adenoma after 10 years as reported by Aggarwal *et. al.* (7).

## References

1. Kammal MM, Adani A, Kotwal MN, Kherdekar MS. Aspiration Cytology of salivary gland tumors. *Ind J Pathol Micro* 1994 ; 37 : 281-87.
2. Wallace AC, MacDongal IT, Hildes JA, Ledderman JM. Salivary gland tumors in Canadian Eskimos. *Cancer* 1963 ; 16,10 : 1338.
3. Davies JNP, Dodge OG, Burkitt DP. Salivary gland tumors in Uganda. *Cancer* 1964 ; 10 : 1310-22.
4. Singh N, Mehdiratta KS, Satyanand. Study of salivary gland tumors. *Ind J Surg* 1968 : 193-206.
5. Thackray AC. Salivary gland tumors. *Proc Roy Soc Med* 1968 ; 61 : 1089.
6. Loke YW. Salivary gland tumors in Malaya. *Br J Surg* 1968 ; 4 : 665-73.
7. Aggarwal M, Khalko J, Mishra SB, Panda AC, Pati K. Salivary gland tumors. *Ind J Pathol Micro* 1996 ; 1 : 69.
8. Boccato P, Atavilla G. FNAC of salivary gland lesions. *Acta Cytol* 1998 ; 42 : 888-98.
9. Robin M, Rankow, Mignogma F. Cancer of sub-lingual salivary glands. *Am J Surg* 1969 ; 118 : 790-95.
10. Virginia A, Lt. Volsti, Perzin. Malignant mixed tumors arising in salivary glands. *Cancer* 1977 ; 39 : 2209-30.
11. Sharkey FE. Systematic evaluation of the world health organization-classification of salivary gland tumors. *AJC P* 1977 ; 67,3 : 272-78.