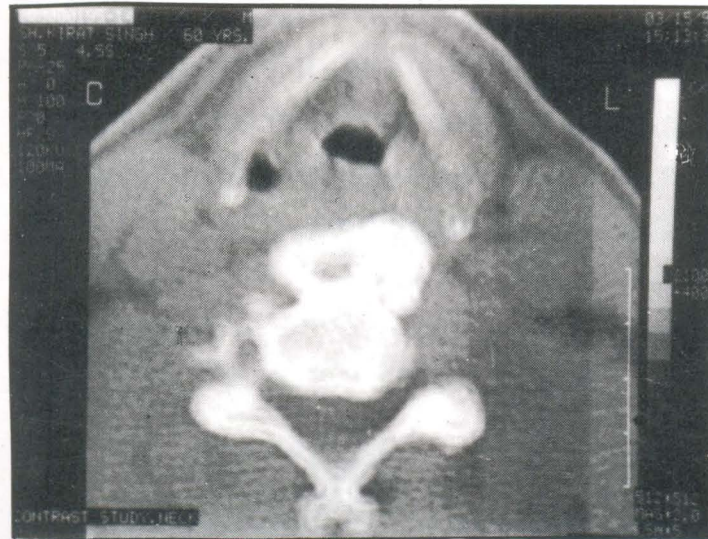


Diffuse Idiopathic Skeletal Hyperostosis (Forestier's Disease, Senile Ankylosing Spondylitis)

Mandeep Singh*, Annil Mahajan**



Plan CT Scan (axial) of the neck at C₄ level showing irregular anterior ossification in the prevertebral space. The neo-ossification is attached with the anterior vertebral margin. The similar lesions were observed in other cervical vertebrae (C₅, C₆, C₇). This CT Scan is of a 60 year old male who presented with history of dysphagia, whose barium swallow revealed hold up of the contrast in the cervical oesophagus because of extraneous compression.

Diffuse Idiopathic Skeletal Hyperostosis (DISH) is a generalized articular disorder, with an axial predilection characterized by ligamentous ossification especially of anterior longitudinal ligament of spine. Thirty percent of patients may have peripheral joint manifestations. It is usually seen in middle aged and elderly patients with male to female ratio of 3 : 1. Patients are frequently asymptomatic but may have stiffness. Some studies have shown an increased incidence of HLA B-27 in patients with DISH. In the spine, dense ossification is found in the cervical and lower thoracic region. Hyperostosis is usually anterior, 1-20 mm thick continuous or flow wax in type. This thick flowing, cortical plaque may indent oesophagus and produce dysphagia at times. The bone laid down is superimposed on a background of normal vertebrae and discs (osteoarthritis can be differentiated as it involves underlying bone and disc also) whereas in contradistinction to ankylosing spondylitis, the sacroiliac joints show neither erosions nor ankylosis. There is no predisposition to spinal fractures, but at times may develop spinal stenosis due to ossified posterior long ligament (OPLL). Florid neo-ossification is also seen at extraspinal sites, around iliac crest, ischia and above acetabulum, on the calcaneum and occasionally fusion between paired long bones.

* Consultant Radiologist, Sigma Diagnostic Centre, Gandhi Nagar, Jammu. ** Consultant General Medicine, Govt. Medical College, Jammu (J&K).
Correspondence to : Dr. Mandeep Singh, Consultant Radiologist, Sigma Diagnostic Centre, 34-CC/C Gandhi Nagar, Jammu-180 004.