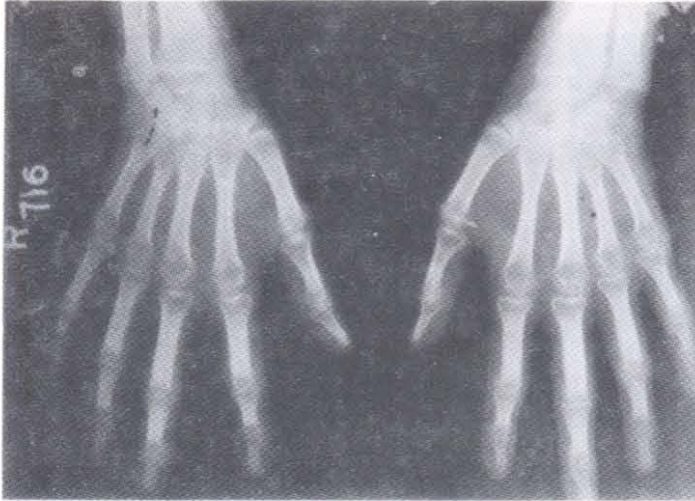




Rheumatoid Hands

Annil Mahajan*, Mandeep Singh**



Anteroposterior radiograph of hands reveals (1) Juxta-articular osteoporosis, (2) Periarticular marginal erosions, (3) loss of interphalangeal joint spaces and (4) fusiform periarticular soft tissue swelling. Patient is a 16 years old female with history of pain and swelling of multiple peripheral joints for 6 months.

Rheumatoid arthritis

A chronic, multisystem disease of unknown etiology affecting women three times more than men. The onset is most frequent during the fourth and fifth decades of life, with 80 percent of all patients developing the disease between the ages of 35 and 50 years. The incidence of Rheumatoid arthritis is more than six times as great in 60 to 64 year old women compared to 18 to 29 year old women. The characteristic feature of this disease is persistent inflammatory synovitis usually involving peripheral joints in a symmetrical distribution. The potential of the synovial inflammation to cause cartilage destruction and bone erosions and subsequent changes in joint integrity is the hall mark of the disease. Two-third of the patients develop joint destruction in first year of the disease. Thus early diagnosis and management with disease controlling antirheumatic drugs holds key in preventing disabling joint deformities.

*Consultant Medicine, **Senior Resident Radiology, Govt. Medical College, Jammu (J&K).

Correspondence to : Dr. Annil Mahajan, Consultant Medicine, Department of Medicine, Govt. Medical college, Jammu (J&K) India.